

## THE IMPACT OF <sup>123</sup>I-META-IODOBENZYLGUANIDINE SCINTIGRAPHY ON DIAGNOSTICS AND FOLLOW-UP OF NEUROBLASTOMA

JAN ABRAHAMSEN, BENTE LYCK, JON HELGESTAD and POUL BÜCHLER FREDERIKSEN

---

**The present retrospective study includes all children suspected for having neuroblastoma, admitted to Odense University Hospital in September 1984 through December 1993. Thirty-six children at the age range of 1 month to 14 years and 10 month were investigated with <sup>123</sup>I-metaiodobenzylguanidine (MIBG). Nineteen children had histologically verified neuroblastoma. Several MIBG scintigraphic examinations were made in all but one of these 19 children. Positive MIBG scintigraphy strengthened the diagnosis and indicated the volume and location of the tumour at diagnosis and during the treatment period. In a few patients only there was some disagreement between results obtained with MIBG scintigraphy and standard investigations as CT-scanning or ultrasonography. MIBG scintigraphy in all cases turned out to be the most sensitive modality.**

---

Radioiodinated meta-iodobenzylguanidine (MIBG) was originally developed for the imaging of the adrenal medulla (1, 2). Due to the similarity between MIBG and noradrenaline it was assumed that MIBG was handled in the same way as noradrenaline by the adrenal medulla, which can be considered a specialized sympathetic ganglion. It turned out that MIBG could be used for scintigraphic visualization of benign and malignant neoplasms of the adrenal medulla and of ectopic pheochromocytomas (2–6). Recently the diagnostic and therapeutic utility of MIBG has been reviewed (7–9).

In paediatric patients the most frequent extracranial solid malignant tumour is neuroblastoma with a reported incidence of 8 cases per 50 000 children a year (10). Intensive chemotherapy and bone marrow transplantation have improved the prognosis of children with advanced neuroblastoma. Differentiation between neuroblastoma and other solid tumours will often be difficult before

surgery, and MIBG scintigraphy seems mandatory for the diagnosis of neuroblastoma. During the diagnostic period, the treatment period and the follow-up period children with neuroblastoma at present usually undergo repeated MIBG scintigraphies with 3–6 months' intervals. Previous studies have shown reasonable agreement between MIBG scintigraphy and standard investigations as CT-scanning and ultrasonography (11). The purpose of the present retrospective investigation was to evaluate MIBG scintigraphy in the diagnosis and monitoring of neuroblastoma by presenting the first 9 years of experience with MIBG examinations of children from a university hospital serving a population of 500 000. Furthermore, the results obtained with MIBG scintigraphy were compared with the results of CT-scanning and ultrasonography.

### Material and Methods

The present retrospective study describes 36 children who went through a MIBG scintigraphy from September 1984 through December 1993 at Odense University Hospital, Denmark. Initially (September 1984–December 1985) <sup>131</sup>I-MIBG scintigraphy was used in a limited number of examinations (15 of a total number of 125; one patient had 6 examinations with <sup>131</sup>I-MIBG). In most cases, however, <sup>123</sup>I-MIBG was used.

---

Received 24 March 1994.

Accepted 18 December 1994.

From the Department of Clinical Physiology and Nuclear Medicine, (J. Abrahamson, B. Lyck, P. Büchler-Frederiksen) and Department of Paediatrics (J. Helgestad), Odense University Hospital, Odense C, Denmark.

Corresponding author: Dr. J. Abrahamson, Department of Clinical Physiology and Nuclear Medicine, Odense University Hospital, Sdr. Boulevard 29, DK-5000 Odense C, Denmark.

**Table 1***Patients with neuroblastoma*

Case No.	Sex	Age	Stage*	MIBG result**	Present status	Number of scintigraphies***
2	F	5 m	IV S	+	Alive	7
4	F	1 y 6 m	III	+	Alive	3(+2)
5	F	1 y 9 m	IV S	+	Alive	7
8	M	1 m	III	+	Dead	1
10	F	5 y 4 m	IV	+	Dead	7
11	M	3 y 3 m	IV	+	Dead	8
13	M	5 y	III	+	Alive	6
15	M	1 m	III	+	Alive	10
17	F	7 y 2 m	IV	+	Alive	3
18	F	5 m	III	+	Alive	6
20	F	1 y 6 m	III	+	Dead	4
23	M	5 y 6 m	IV	+	Dead	6
24	M	2 y 9 m	IV	+	Dead	5
26	M	10 y 10 m	III	+	Dead	11(+1)
29	F	6 y 4 m	IV	+	Dead	4
32	F	2 y 4 m	IV	+	Dead	5(+1)
33	M	3 y 6 m	II	+	Alive	2
34	F	2 m	IV S	+	Alive	7
35	M	5 y 4 m	IV	+	Dead	4

\* Stage according to Evans et al. (35).

\*\* MIBG-scintigraphy: full agreement with other diagnostic procedures: yes (+)/no (-) at time of diagnosis.

\*\*\* Number in parentheses indicates MIBG treatments.

**Table 2***Patients without neuroblastoma*

Case No.	Sex	Age	Diagnosis	MIBG*	Number of scintigraphies
1	M	7 y 6 m	No tumor	+	1
3	F	1 y	Cerebral tumor	+	1
6	F	9 m	No tumor	+	1
7	M	1 y 3 m	Wilms' tumor	+	1
9	M	3 y 10 m	Wilms' tumor	+	1
12	F	11 m	No tumor	(+)	1
14	F	14 y 10 m	Dysgerminoma	+	1
16	F	2 y 11 m	Wilms' tumor	+	1
19	M	1 y 2 m	No tumor	+	2**
21	M	1 y 7 m	Wilms' tumor	+	1
22	M	1 y 1 m	No tumor	+	2***
25	M	7 y 11 m	Wilms' tumor	+	1
27	M	4 y 1 m	Wilms' tumor	+	1
28	M	12 y 7 m	Ewing's sarcoma	+	1
30	F	13 y 9 m	Cerebral tumor	+	1
31	M	14 m	Wilms' tumor	+	1
36	M	5 y 4 m	Leukemia (ALL)	+	1

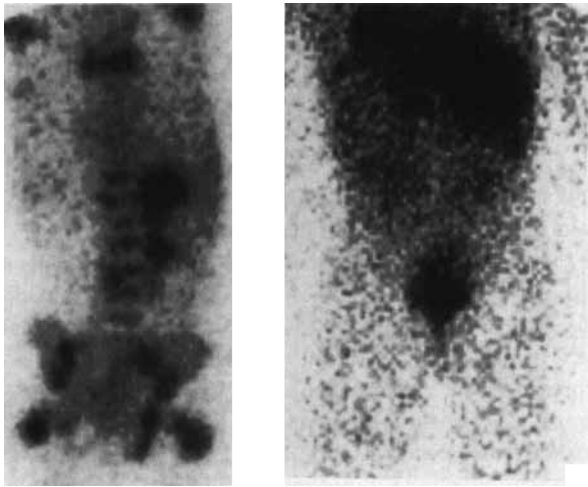
\* MIBG scintigraphy: full agreement with other diagnostic procedures: yes (+)/no (-) at time of diagnosis.

\*\* Still elevated level of catecholamines.

\*\*\* Abnormal accumulation in the lungs at the first examination; reason unknown.

For diagnostic investigations with  $^{131}\text{I}$ -MIBG the standard activity was 18 MBq independent of weight. When  $^{123}\text{I}$ -MIBG was used, the activity was 74 MBq for children weighing less than 8 kg, 111 MBq for children between 8 and 20 kg, and 185 MBq for children weighing more than

20 kg. MIBG was injected in the morning and images were made 4, 24 and 48 h after injection. The head and the whole truncus were scanned with AP- and PA-projections. To block the thyroid gland, potassium iodid was administered twice daily from the day prior to MIBG injection



*Fig. 1.* Patient No 23. A 5 year and 6 months old boy with histologically verified neuroblastoma with bone marrow metastases. The initial MIBG scintigraphy shows accumulation in the region of the left suprarenal gland. Extended bone marrow accumulation is seen (panel A). The primary tumour is surgically removed and chemotherapy initiated. One year later no bone marrow involvement is demonstrated with MIBG scintigraphy (panel B).

and during the following three days. The gamma camera used was from General Electric, preferably Maxicamera 535. A 'STAR'-computer was used in most investigations to increase the contrast between high and low uptake zones. Computer images with a matrix dimension of  $64 \times 64$  pixels (300s, 300–400 000 counts) were made.  $^{131}\text{I}$ -MIBG was obtained from the Institute for Energy Technology, Kjeller, Norway and  $^{123}\text{I}$ -MIBG from Cygne, Eindhoven, The Netherlands.

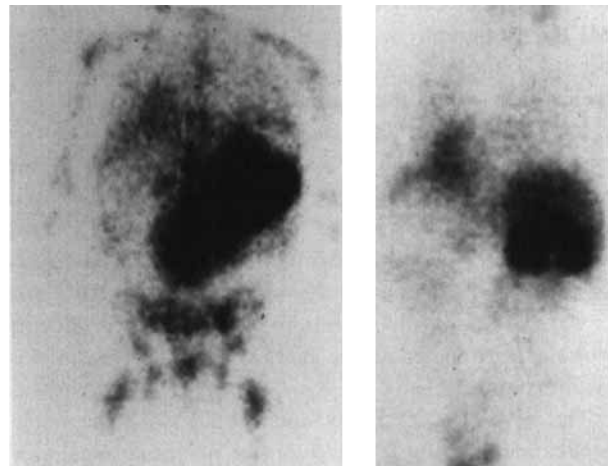
Bone scintigraphy with  $^{99\text{m}}\text{Tc}$ -methylenediphosphonat (MDP, Amersham, England) was carried out in 75% of the patients. In some cases liver scintigraphy was performed with  $^{99\text{m}}\text{Tc}$ -sulfurcolloid (Department of Nuclear Medicine, Odense University Hospital, Denmark).

Throughout the years the MIBG-scintigraphies were examined by the same specialist, who had no prior knowledge of the diagnosis at the time of the first MIBG scintigraphy. Tumour uptake was recorded when the level was similar to or higher than that in the salivary glands, myocardium and liver.

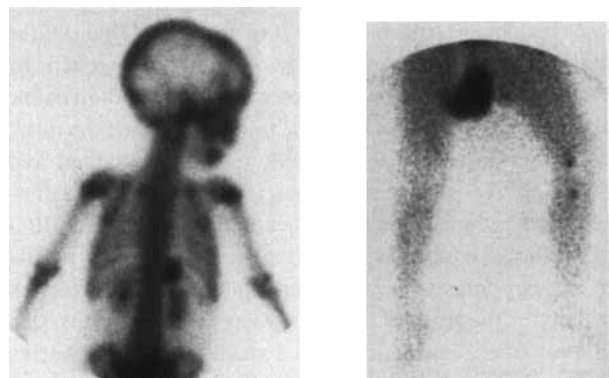
### Results

MIBG scintigraphies were performed in 36 paediatric patients of whom 19 had histologic verified neuroblastoma (Table 1).

All children with neuroblastoma went through one initial diagnostic MIBG-scintigraphy (Table 1). Eighteen of these patients had follow-up studies to evaluate the effect



*Fig. 2.* Patient No. 10. A 5 years and 4 months old girl with histologically verified neuroblastoma in abdomen and bone marrow. Initial MIBG scintigraphy showed accumulation in a huge intraabdominal tumour and in the bone marrow (panel A). The patient received chemotherapy. Four months later the tumour size was reduced significantly (panel B).



*Fig. 3.* Patient No. 5. A 21-month-old girl, where biopsy from proximal tibia showed embryonal rhabdomyosarcoma. In the search for possible metastases a bone scintigraphy was done (panel A), this showed extraskkeletal accumulation in the region of the left suprarenal gland. The finding was confirmed with MIBG scintigraphy and MRI and the tumour was removed. Histological diagnosis was neuroblastoma. Revision of the initial histological diagnosis was interpreted as neuroblastoma. Furthermore MIBG showed a rest tumour in the left leg (panel B). The patient went through chemotherapy and is still alive.

of the therapy. Sex, age and agreement between MIBG scintigraphy, CT-scanning and ultrasonography are given in Tables 1 and 2. Fifteen patients with neuroblastoma went through an initial bone scintigraphy. Extraskkeletal accumulation was found in 8 (53%) of these patients.

In patient No. 12 the initial ultrasound investigation and CT-scanning were falsely positive and suggested a tumour

(5 × 1.5 cm) medially to the left kidney. Despite a negative MIBG scintigraphy a surgical exploration was performed but no abnormalities were found. Furthermore, peroperatively ultrasound investigation of retroperitoneum only showed pancreas in its normal position. The CT-scanning was reviewed and the finding could be explained by the localization of the pancreas. The patient is still alive and without any signs of tumour. In patient No. 29 CT-scanning and ultrasound investigation initially failed to visualize the primary tumour which was revealed by MIBG and confirmed during an operation. Among the 17 patients without neuroblastoma the most common neoplasm was Wilms' tumour (Table 2).

The nosologic sensitivity and specificity of the initial MIBG scintigraphy for detection of neuroblastoma were 100%. In the follow-up period biptic controls were available in a few patients only, and the accuracy could therefore not be established. Three patient stories are presented together with Figures 1–3.

### Discussion

MIBG resembles noradrenaline and is handled in much the same way by the tissue derived from the sympathetic system. This is the basis for the use of MIBG in the diagnosis of neuroblastoma as originally suggested by Wieland et al. (1). The close resemblance to noradrenaline also explains why drugs known to interfere with the noradrenaline storage (e.g., reserpine and guanethidine) and the re-uptake of noradrenaline (e.g., tricyclic antidepressant and cocaine) greatly influence the uptake of MIBG (12). This also explains the normal accumulation of MIBG in salivary glands, myocardium and liver. As expected activity in the bladder due to released radio iodine is seen in most cases. Furthermore, in a small number of patients the normal adrenal medulla, lungs and spleen are visualized. Normally, however, no detectable uptake of MIBG is found in bone or bone marrow (13). The normal accumulation of MIBG in the myocardium may in the future be used to assess the degree of innervation of the heart, especially in patients with heart diseases, e.g., ischemic disease (14, 15). Neuroblastoma is a serious disease. The prognosis is mostly bad, but not hopeless. The differentiation against nephroblastoma and some other solid tumours in children is very important and often difficult with classical methods. MIBG scintigraphy is an excellent modality for establishing the diagnosis and monitoring after treatment (5). The 100% sensitivity and specificity at the time of diagnosis found in the present investigation is in agreement with most other investigations (7, 8, 16).

MIBG scintigraphy demonstrates tumour involvement in bone marrow as well as in bone but the exact tissue location cannot be disclosed in the scintigram. Bone scintigraphy can reveal bone metastases, but does not show bone marrow involvement. Recently some authors

(e.g. 17) have reported a rather close agreement between MIBG and bone scintigraphy. However, bone scintigraphic uptake is not specific for tumour and after tumour remission focal bone uptake will persist for months. Bone scintigraphy is often used in the early evaluation of neoplastic lesions and in neuroblastoma patients extra-skeletal tumour uptake is often seen. In the present study, initial bone scintigraphy demonstrated such accumulation in 53% of the patients with neuroblastoma which is in agreement with other reports (18, 19). The explanation for this uptake may be calcification in neuroblastoma, which has been reported in radiological investigations (20). Furthermore, CT-scanning has demonstrated calcifications in 85% of soft tissue neuroblastomas (21). For the detection of extra-skeletal neuroblastoma, MIBG is clearly superior to bone scintigraphy (17), but incidentally bone scintigraphy may have additional value. A bone scintigraphy with skeletal accumulation should be regarded as indicative of bone metastases even if radiographs and bone marrow aspiration are normal. Compared with conventional radiographic studies bone scintigraphy tends to show more wide-spread metastatic disease (22). Scintigraphic evidence of bone metastases in neuroblastoma is associated with a very poor prognosis (23). It has been stated that MIBG sometimes can fail to detect bone lesions from neuroblastoma which can be detected by bone scintigraphy (24). However, according to the present results MIBG scintigraphy is more sensitive than bone scintigraphy.

Newer approaches to the diagnosis of neuroblastoma include radiolabelled monoclonal antibodies, magnetic resonance imaging (MRI, 25) and the use of radiolabelled somatostatin or its analogue, octreotide. Radiolabelled monoclonal antibodies seem to have the same sensitivity as MIBG scintigraphy for detection of neuroblastoma (26). Recently MRI, <sup>123</sup>I-MIBG, and bone marrow aspiration and biopsy were compared in the diagnosis of bone/bone marrow involvement (27). The authors concluded that MRI and <sup>123</sup>I-MIBG were superior to bone marrow sampling. The somatostatin analogue octreotide can be labelled with <sup>123</sup>I or <sup>111</sup>In and uptake in neuroblastoma was recently reported (28).

In the present study no clear-cut value of the catecholamine analyses could be found. During the period of the present investigation the urine catecholamine assay and sampling were not standardized, and added no reliable data at the time of diagnosis or during treatment and follow-up. However, excess catecholamines and their metabolites can be found in the blood and urine from these patients which is the background for the suggested screening for neuroblastoma by measuring catecholamines in the infants (10, 29, 30, 31). In screening for neuroblastoma in infancy, measurements of catecholamines still is the method of choice (10).

For the diagnosis of neuroblastoma <sup>123</sup>I-MIBG scintigraphy is very useful with nosologic sensitivity and specific-

ity approaching 100% (32–34). Once the suspicion of neuroblastoma is raised, MIBG scintigraphy is inevitable for typing and localisation. Repeated MIBG scintigraphies for monitoring the effect of treatment and the posttreatment course could be questioned, because of the close agreement with CT-scanning and ultrasound investigations. In most cases, however, MIBG was in the present study superior to the other modalities.

#### ACKNOWLEDGEMENT

We thank Mrs. Anette Larsen for excellent secretarial assistance.

#### REFERENCES

- Wieland DM, Wu J-I, Brown LE, Mangner TJ, Swanson DP, Beierwaltes WH. Radiolabelled adrenergic neuron-blocking agents: adrenomedullary imaging with [<sup>131</sup>I]iodobenzylguanidine. *J Nucl Med* 1980; 21: 349–53.
- Sisson JC, Frager MS, Valk T, et al. Scintigraphic localization of pheochromocytoma. *New Engl J Med* 1981; 305: 12–7.
- Kimmig B, Brandeis WE, Eisenhut M, Bubeck B, Hermann HJ, Winkel K zum. Scintigraphy of a neuroblastoma with I-131 meta-iodobenzylguanidine. *J Nucl Med* 1984; 25: 773–5.
- Geatti O, Shapiro B, Sisson JC, et al. Iodine-131 metaiodobenzylguanidine scintigraphy for the location of neuroblastoma: preliminary experience in ten cases. *J Nucl Med* 1985; 26: 736–42.
- Hoefnagel CA, Voûte PA, Kraker J de, Marcuse HR. Total-body scintigraphy with <sup>131</sup>I-meta-iodobenzylguanidine for detection of neuroblastoma. *Diag Imag Clin Med* 1985; 54: 21–7.
- Bomanji J, Levison DA, Flatman WD, et al. Uptake of iodine-123 MIBG by pheochromocytomas, paragangliomas, and neuroblastomas: a histopathological comparison. *J Nucl Med* 1987; 28: 973–8.
- Troncone L, Rufini V, Montemaggi P, Danza FM, Lasorella A, Mastrangelo R. The diagnostic and therapeutic utility of radioiodinated metaiodobenzylguanidine (MIBG). *Eur J Nucl Med* 1990; 16: 325–35.
- Hoefnagel CA, Voûte PA, Kraker J de, Marcuse HR. Radionuclide diagnosis and therapy of neural crest tumours using iodine-131 metaiodobenzylguanidine. *J Nucl Med* 1987; 28: 308–14.
- Hoefnagel CA, Kraker J de, Voûte PA, Olmos RAV. Preoperative [<sup>131</sup>I]metaiodobenzylguanidine therapy of neuroblastoma at diagnosis (“MIBG de novo”). *J Nucl Biol Med* 1991; 35: 248–51.
- Carlsen NLT. Neuroblastoma: epidemiology and pattern of regression. *Am J Ped Hematol Oncol* 1992; 14: 103–10.
- Schmiegelow K, Siimes MA, Agertoft L, et al. Radioiodobenzylguanidine scintigraphy of neuroblastoma: conflicting results, when compared with standard investigations. *Med Pediatr Oncol* 1989; 17: 126–30.
- Solanki KK, Bomanji J, Moyes J, Mather SJ, Trainer PJ, Britton KE. A pharmacological guide to medicines which interfere with the biodistribution of radiolabelled meta-iodobenzylguanidine. *Nucl Med Commun* 1992; 13: 513–21.
- Gelfand MJ. Meta-iodobenzylguanidine in children. *Semin Nucl Med* 1993; 23: 231–242.
- Guertner C, Klepzig H, Maul FD, et al. Noradrenaline depletion in patients with coronary artery disease before and after percutaneous transluminal coronary angioplasty with iodine-123 metaiodobenzylguanidine and single-photon emission tomography. *Eur J Nucl Med* 1993; 20: 776–82.
- Shakespeare CF, Page CJ, O’Doherty MJ, et al. Regional sympathetic innervation of the heart by means of metaiodobenzylguanidine imaging in silent ischemia. *Am Heart J* 1993; 125: 1614–21.
- Bouvier JF, Philip T, Chauvot P, et al. Pitfalls and solutions in neuroblastoma diagnosis using radioiodine MIBG: our experience about 50 cases. *Prog Clin Biol Res* 1988; 271: 707–20.
- Shulkin BL, Shapiro B, Hutchinson RJ. Iodine-131-metaiodobenzylguanidine and bone scintigraphy for the detection of neuroblastoma. *J Nucl Med* 1992; 33: 1735–40.
- Young G, L’Heureux P. Extraosseous tumour uptake of 99m technetium phosphate compounds in children with abdominal neuroblastoma. *Pediatr Radiol* 1978; 7: 159–63.
- Smith FW, Gilday DL, Ash JM, Reid RH. Primary neuroblastoma uptake of 99m technetium methylene diphosphonate. *Radiology* 1980; 137: 501–3.
- Merten DF, Kirks DR. Diagnostic imaging of paediatric abdominal masses. *Pediatrics Clin N.A.* 1985; 32: 1397–425.
- Pizzo PA, Horowitz ME, Poplack DG, Hays DM, Kun LE. Solid tumours of childhood. In: DeVita VT, Hellman S, Rosenberg SA, eds. *Cancer: principles & practice of oncology*. Philadelphia: JB Lippincott Co, 1993: 1749–55.
- Heisel MA, Miller JH, Reid BS, Siegel SE. Radionuclide bone scan in neuroblastoma. *Pediatrics* 1983; 71: 206–9.
- Daubenton JD, Fisher RM, Karabus CD, Mann MD. The relationship between prognosis and scintigraphic evidence of bone metastases in neuroblastoma. *Cancer* 1987; 59: 1586–9.
- Gordon I, Peters AM, Gutman A, Morony S, Dicks-Mireaux C, Pritchard J. Skeletal assessment in neuroblastoma—the pitfalls of iodine-123-MIBG scans. *J Nucl Med* 1990; 31: 129–34.
- Maris JM, Evans AE, McLaughlin AC, et al. <sup>31</sup>P Nuclear magnetic resonance spectroscopic investigation of human neuroblastoma in situ. *New Engl J Med* 1985; 312: 1500–5.
- Yeh SDJ, Larson SM, Burch L, et al. Radioimmunodetection of neuroblastoma with iodine-131-3F8: correlation with biopsy, iodine-131-metaiodobenzylguanidine and standard diagnostic modalities. *J Nucl Med* 1991; 32: 769–76.
- Corbett R, Fullbrook A., Meller S, Flower M. <sup>123</sup>Iodine meta-iodobenzylguanidine single photon emission computed tomography in the assessment of children with neuroblastoma. *Prog Clin Biol Res* 1991; 366: 479–85.
- Oei HY, Krenning EP, Lamberts SWJ. Somatostatin receptor imaging using octreoscan In 111. Petten, The Netherlands: Mallinckrodt Medical BV Publication, 1991.
- Sawada T, Sugimoto T, Tanaka T, et al. Number and cure rate of neuroblastoma cases detected by the mass screening program in Japan: future aspects. *Med Pediatr Oncol* 1987; 15: 14–7.
- Sawada T, Nagahara N, Yamamoto K, et al. Mass screening for neuroblastoma in Japan. *Acta Paediatr Jpn* 1990; 32: 725–33.
- Tuchman M, Lemieux B, Auray-Blais C, et al. Screening for neuroblastoma at 3 weeks of age: methods and preliminary results from the Quebec neuroblastoma screening project. *Pediatrics* 1990; 86: 765–73.

32. Jacobs A, Delree M, Desprechins B, et al. Consolidating the role of \*I-MIBG-scintigraphy in childhood neuroblastoma: five years of clinical experience. *Pediatr Radiol* 1990; 20: 157–9.
33. Moyes J, McCready VR, Fullbrook A. *Neuroblastoma, MIBG in its diagnosis and management*. Berlin, Heidelberg; Springer-Verlag, 1989.
34. Parisi MT, Greene MK, Dykes TM, Moraldo TV, Sandler ED, Hattner RS. Efficacy of metaiodobenzylguanidine as a scintigraphic agent for the detection of neuroblastoma. *Invest Radiol* 1992; 27: 768–73.
35. Evans AE. Staging and treatment of neuroblastoma. *Cancer* 1980; 45: 1799–802.