

DEFINITIVE RADIOTHERAPY FOR CARCINOMA OF THE ORAL TONGUE

TO-WAI LEUNG, ANNE W. M. LEE and DAVID K. K. CHAN

This is a retrospective analysis of 117 patients with carcinoma of the oral tongue treated by definitive radiotherapy during 1979-1990. Sixty-seven per cent of patients presented with T1-2 disease. Their cumulative incidence of local failure was 10% (5/50) for those suitable for treatment with implant alone, 81% (13/16) for those treated with external irradiation alone and 67% (8/12) after combined treatment. These differences could largely be explained by selection factors as smaller and less bulky tumours generally were selected for implant treatment. Among the patients who achieved local control, there was no incidence of regional relapse (0/9) for those with elective neck irradiation, but 33% (15/46) for those without. This incidence correlated with size of primary tumour. Radiotherapy achieved effective local control in 13% (5/39) of T3-4 tumours, and regional control in 43% (12/28) of N1-3 cases. Only 32% (24/76) of patients with local and/or regional recurrence were successfully salvaged. Ways of improving the treatment are discussed.

Achievement of locoregional control is crucial for survival of patients with carcinoma of the oral tongue, as very few die of distant failure alone. To achieve this primary goal with minimal dysfunction is a great challenge to the oncologist. The choice of treatment for local and regional disease remains controversial. While surgery (with or without postoperative irradiation) is the most widely accepted modality for relatively advanced cases (1), recommendation for early primary tumours varies from glossectomy to different modes of radiation therapy (RT) (2-10). Policy adopted for clinically node-negative cases varies from observation (11) to elective neck dissection (12, 13) or irradiation (14-16).

The present study includes a retrospective analysis of a series of patients with carcinoma of the oral tongue treated primarily by RT with curative intent. Based on the findings the effectiveness and limitation of RT is analysed and possible ways to improve the treatment are discussed.

Material and Methods

During the years 1979 to 1990, 125 previously untreated patients with carcinoma of the oral tongue (the part anterior to the circumvallate papillae) were selected for definitive RT with curative intent at our institute. Only 117 were evaluable since 8 patients did not complete the planned treatment. The male to female ratio was 1.8:1, and the median age 56 years (range = 19-80 years). All patients were observed until death or for a minimum period of 2 years (including those who were subsequently lost to follow-up). Histologically, all were squamous cell carcinomas; 52% well differentiated, 28% moderately, 7% poorly differentiated, and 13% unclassifiable concerning differentiation. The primary tumour was located at the lateral border of the tongue in 82%, at the inferior surface in 13%, at the dorsum in 3.5% and at the tip in 1.5% of the patients. Table 1 shows the TNM and stage distribution as classified by the fourth edition of the American Joint Committee for Cancer Staging and End Results Reporting (1992). None of the patients had distant metastases at presentation, and the ratio of early (I, II) to advanced (III, IV) stage was 1.5:1. Only 24% of patients had overt regional involvement at the time of diagnosis: 8.5% presented as N1, 14.5% N2, and 1% N3.

Various treatment techniques and doses were used depending on the extent of disease (Table 2). The policy

Received 14 January 1993.

Accepted 23 April 1993.

From Institute of Radiology and Oncology, Queen Elizabeth Hospital, Kowloon, Hong Kong.

Correspondence to: Dr. T. W. Leung, Institute of Radiology and Oncology, Queen Elizabeth Hospital, Wylie Road, Kowloon, Hong Kong.

Table 1

TNM and stage distributions (%) according to the AJCC staging system

A. T and N categories

	N0 (%)	N1 (%)	N2 (%)	N3 (%)	Total (%)
T1	45 (39)	0	0	0	45 (39)
T2	26 (22)	3 (3)	4 (3)	0	33 (28)
T3	5 (4)	1 (1)	1 (1)	0	7 (6)
T4	13 (11)	6 (5)	12 (10)	1 (1)	32 (27)
Total	89 (76)	10 (9)	17 (14)	1 (1)	117 (100)

B. Stage

Stage	Number (%)
I	45 (39)
II	26 (22)
III	9 (8)
IV	37 (31)

All patients were M0.

Table 2

Irradiation methods used in different stages

Irradiation method	Number of patients in each stage				
	I	II	III	IV	Total
Implant alone	38	12	1	0	51
Ext. RT alone	4	7	5	36	52
Ext. RT + implant	3	7	3	1	14

during the analysed period was to treat small, non-bulky primary tumours with interstitial implant alone, and to withhold elective neck treatment in node-negative patients. Advanced cases were treated with external irradiation with and without combination with interstitial implant, while surgery was reserved for salvage. Thus, 51 patients were treated with implant alone; 42 with radium needles, 6 with cesium-137 needles and 3 with iridium-192 wires. All except one patient had T1–2 disease. The prescribed dose was calculated according to the Paterson and Parker's rules for needle implants (17), and the Paris system for iridium wire implants (18). The median dose was 70 Gy over 7 days (range 58–80 Gy). For those treated with needle implant, an average of 7 sources containing a total of 10 mg radium-equivalent was used to treat a volume of 15 cm³.

All the remaining patients were treated with external irradiation or a combination of external and interstitial irradiation. Among these patients, 21 had T1–2 N0 disease and they were not treated with implant alone for the following reasons: bulky disease (10 pts), technical difficulties due to posterior location (8 pts), unsatisfactory dosimetry (1 pt), poor initial response (1 pt) and patient's refusal (1 pt).

The most commonly used method for external irradiation was shrinking-field technique with lateral opposing facial-cervical fields. Individual cobex cast with tongue depressor was used for immobilisation. The upper cervical regions (including submental, submandibular and subdiaphragmatic nodes) were generally included into the primary target. For those treated by external RT alone, the median total dose was 65 Gy (range 50–80 Gy), and only 29% (15/52) had doses of more than 68 Gy. For the 14 patients irradiated by combined treatment, a median dose of 50 Gy (range 10–60 Gy) was given by external RT and 40 Gy (range 30–70 Gy) by implant.

Only 48% (29/60) of patients with local recurrences were treated with glossectomy and 56% (24/43) of patients with regional recurrences underwent neck dissection (with or without postoperative irradiation) as salvage. The remaining patients with recurrence were treated palliatively.

The survival rates were based on actuarial measurement from the date of diagnosis and calculated by the Kaplan-Meier method (19). Both persistent tumour and recurrence were included as endpoints for failure-free survival (FFS), and disease specific death was used as endpoints for actuarial survival (AS).

Results

Altogether 77 (66%) patients failed: 60 locally, 43 regionally, and two at distant sites. Ninety per cent (95/105) of all failures manifested within two years from completion of primary treatment. The actuarial 10-year local-FFS rate for the whole series was 44% (Fig. 1). The cumulative incidence of local failure increased with T-category and it was 18% for T1 tumours, 55% for T2, 71% for T3, and 91% for T4.

Table 3 shows the failure rates following different treatments. The highest control rate was obtained in T1 tumours treated by implant alone. For patients with T1–2 disease, the failure rate was 10% (5/50) following implant, 67% (8/12) after combined treatment, and 81% (13/16) after external RT. These differences were probably mainly due to selection factors as less bulky and smaller tumours were selected for treatment with implant. In the combined group, the mean dose contributed by implant was 49 Gy in patients who achieved local control, but only 39 Gy among those who failed. All except three of the patients with T3–4 tumours were treated by external irradiation alone and their local control rate was only 8% (3/36).

The 10-year actuarial regional-FFS rate for the whole series was 58% (Fig. 1). The cumulative incidence of regional failure was 30% (27/89) for node-negative and 57% (16/28) for node-positive cases. Among the 43 patients who developed regional relapse, 27 had concurrent local recurrence. It is difficult to tell whether re-seeding was the cause of nodal deposits. Hence, further analysis was concentrated on patients with regional failure alone.

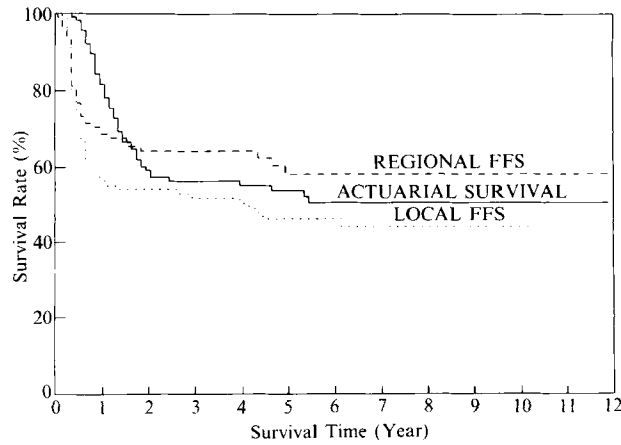


Fig 1. Actuarial survival and failure-free survival (FFS) curves for the whole group.

While none of the 9 patients with elective neck irradiation failed regionally, 33% (15/46) of those without prophylactic irradiation subsequently showed lymph node involvement. All except one recurred in the ipsilateral side. Ten patients relapsed in the upper cervical regions, three in the mid neck, two in both levels, and none in the lower neck. The regional relapse rate was 24% (8/34) for T1 and 55% (6/11) for T2 cases. Strong correlation with the size of primary tumour could be demonstrated and the regional relapse rate increased from 13% for lesions ≤ 1 cm, to 75% for those > 3 cm (p-value of trend test = 0.008) (Table 4).

Altogether 24 (32%) patients achieved second remission and remained disease-free up to a median follow-up of 3.6 years from salvage treatment. Of the 33 patients with local recurrence alone, only 20 were fit for glossectomy and 11 were salvaged. All except one of the 16 patients with regional relapse alone were treated with neck dissection (with or without postoperative RT) and 60% (9/15) of them achieved complete regional remission. Among patients with both local and regional failure, only 15% (4/27) were salvaged.

Two patients (2%) developed lung metastases and one of them had preceding regional recurrence. Eleven patients

Table 4

Relationship between size of primary tumour and regional recurrence rate in 46 local failure-free patients without prophylactic neck treatment

Size of primary (cm)	Cumulative rate of regional failure	
	n	%
≤ 1	2/15	13
1.1-2	6/19	32
2.1-3.0	4/8	50
3.1-4	2/3	66
4.1-5.0	1/1	100

(9%) developed a second primary cancer: six of them were carcinoma in the head and neck region, four were lung cancer and one oesophageal cancer.

The final outcome and the causes of death were listed in Table 5. Of the 24 patients who died of other causes or were lost to follow-up, none had evidence of disease. The 10-year AS rate for the whole series was 51% (Fig. 1). Survival varied with stage of disease: the 5-year AS rate was 84% in stage I and 18% in stage IV (Fig. 2).

Complications. Two patients had profuse bleeding on removal of implant needles and one of them developed laryngeal oedema requiring temporary tracheostomy. Most patients treated with external irradiation had varying degree of xerostomia. Five patients had symptomatic necrosis of the mandible and six soft tissue necrosis. Three of those with osteonecrosis had received external irradiation alone, two with soft tissue necrosis had been treated by combined method, while the remaining ones had been

Table 5

Outcome of the whole group

Clinical outcome	Number of patients
Alive without disease	40 (34%)
Died of	
carcinoma of tongue	53 (45%)
second primary	7 (6%)
intercurrent disease	6 (5%)
Lost to follow-up	11 (10%)

Table 3

Local failure rates according to different treatment methods and T-category

Irradiation method	Cumulative incidence of local failure (%)				
	T1	T2	T3	T4	Total
Implant	3/38 (8)	2/12 (17)	0/1 (0)	0	5/51 (10)
Ext. RT alone	3/4 (75)	10/12 (83)	5/5 (100)	28/31 (90)	46/52 (88)
Ext. RT + implant	2/3 (67)	6/9 (67)	0/1 (0)	1/1 (100)	9/14 (64)
Total	8/45 (18)	18/33 (55)	5/7 (71)	29/32 (91)	60/117 (51)

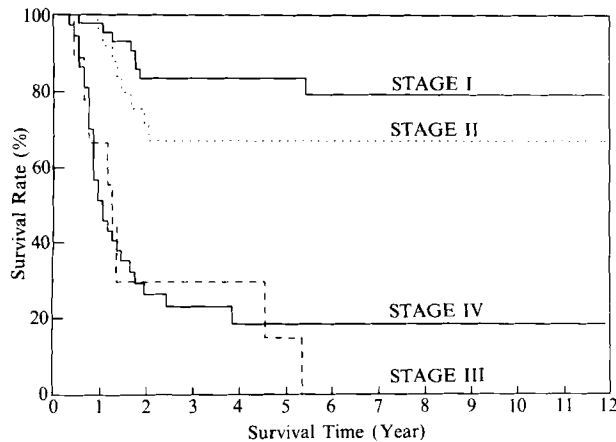


Fig. 2. Actuarial survival curves for different stages.

treated solely by implant. One patient with bone necrosis required segmental mandibulectomy and iliac crest graft. All the other ones were healed with conservative treatment. No treatment-related mortality was observed. X-rays of the mandible was not routinely taken and only symptomatic cases were recorded, which may possibly account for the relatively low complication rate observed.

Discussion

Selection of treatment for carcinoma of the tongue is largely determined by extent of disease, location and size of the primary tumour. It is therefore difficult, or impossible, to compare the effectiveness of different methods in a retrospective analysis. Unfortunately, there is yet no report of prospective randomized studies on this disease. Results of past experience remain the most important guide for future attempts of improvement.

Optimization of treatment for early tumours naturally attracts the greatest attention. With interstitial implant alone or as part of the treatment, median local control rates for T1 and T2 tumours of 86% and 80% respectively have been reported (2, 4, 7). This compares favourably with classical surgical series: the corresponding reported control achieved by partial glossectomy being 85% for T1 and 77% for T2 (10). With the important advantage of organ preservation, RT with implant is apparently a good choice. In the present series we achieved a control rate of 90% in T1–2 tumours suitable for treatment with implant alone (Table 3). Important for selection of treatment are also considerations concerning occult deposits in the cervical lymph nodes. The decision to treat the clinical negative neck should be based on knowledge of the incidence of occult lymphatic involvement, effectiveness/morbidity of prophylactic treatment, and the chance of successful salvage. The reported incidence of occult node deposits in clinically node-negative patients ranges from 27% to 44% (10, 11, 14, 16, 20–22). Spiro et al. (22, 23) suggested that

the thickness of primary tumour is a more accurate predictor of involvement than simple T-classification. In our present study there was a good correlation between the incidence of the reported failure and the size of the primary tumour (Table 4). We agree with Bradfield et al. (24) that patients with small T1 tumours could be excluded from elective neck node treatment as their risk of regional recurrence is very low. However, among patients with controlled T1 primary in our series, the incidence of regional relapse increased from 13% for lesions ≤ 1 cm to 32% for those 1.1–2 cm, if prophylactic neck treatment was withheld.

Our results agree with several previous reports and show that a high regional control rate can be achieved with elective neck irradiation at a total dose of 45–50 Gy (14–16). Coverage of ipsilateral upper and mid neck may suffice for unilateral lesions, as only one case in our series recurred at the contralateral side and none recurred in the supraclavicular fossa.

Data from surgical series have given similar information. Elective radical neck dissection for patients with squamous carcinoma of oral cavity revealed occult nodal metastases in 34% of N0 patients, and only 3% involved level IV nodes (20). Most authors have suggested that modified neck dissection, which is associated with less morbidity, is adequate in clinically node-negative cases (12, 13, 20, 25–27).

The result of salvage treatment is far from satisfactory. The reported salvage rate for regional recurrence ranges from 30 to 56% (21, 22, 28). Although we achieved regional salvage in 60% of patients with local control and no previous neck irradiation, only 15% of those with both local and regional recurrence achieved a second remission. Regarding patients with local recurrence alone, only 33% were successfully salvaged by glossectomy. The importance of primary locoregional control cannot be over-emphasized.

According to our recommendation, elective neck treatment should be given to all patients except those with a primary tumour ≤ 1 cm in size. Prophylactic RT and neck dissection are equally good, but it is often ideal if the neck and the primary tumour can be simultaneously irradiated. However, the overlap between the cervical field and the implant volume may give special difficulties.

Although Korb et al. (29) found no difference in local control rate between patients with T1–2 lesions treated with versus without implant, a majority of authors have reported that a high dose brachytherapy is necessary for securing a good local control (3, 7, 9, 30). For patients treated with combined external and interstitial irradiation, the results have been dependent on the proportion of the dose contributed by the implant. Our data are in full agreement with these findings.

Different approaches have been used to solve the dose distribution problem. Mendenhall et al. (30) and Horiuchi

et al. (7) applied a rather low external beam dose followed by implant. Wang (5) preferred external RT twice daily to 50 Gy in conjunction with intra-oral cone electron beam boost instead of interstitial implant. Wendt et al. (9) employed primary surgery for most oral tongue cancers, adding postoperative radiotherapy only if there were poor prognostic signs.

For maximum chance of local control and tongue preservation, we recommend that all primary tumours suitable for treatment with implant alone should be so treated. Instead of using external RT, we would prefer neck dissection both as elective treatment for patients with primaries >1 cm and as therapeutic treatment for node-positive patients. The local control rate of T3-4 tumour treated by external irradiation alone is poor (Table 3) and it is unlikely that an increase of the dose could improve the results dramatically (7). The best treatment for these extensive tumours is probably glossectomy and neck dissection (1) with added postoperative irradiation if there is evidence of multiple node involvement or extracapsular spread (1, 12, 13, 25, 27, 31). If neoadjuvant or adjuvant chemotherapy (such as 5-FU + cisplatin) can improve the result in these cases is still unknown but at present tested in several on-going randomised multicentre studies.

Although 90% of the failures in our series became manifest within two years, life-long follow-up is necessary as these patients are prone to develop a second malignancy at a rate as high as 3.7% per year (32). For patients with a second primary in the head and neck region, the possibility of salvage treatment depends very much on the initial treatment method. Radical salvage attempt was more often feasible for patients treated initially with implant alone than for those who had received external irradiation or combined treatment (33). Previous elective neck irradiation seems to almost eliminate radiotherapy as a possible option (14).

Survival of patients with carcinoma of tongue varies with the extent of disease. In our series the 5-year survival decreased from 84% for stage I to 18% for stage IV (Fig. 2). To improve the overall cure rate and the chance of tongue preservation, more effort should be directed towards education of the public concerning early detection.

ACKNOWLEDGEMENTS

The authors wish to thank Dr. C. M. Lo, Mr. W. H. Ho, and Mr. K. M. Poon for assistance in data collection, Mr. Oscar Mang for the figures; and finally all the staff of the Institute of Radiology and Oncology for their contribution in the management of this series of patients.

REFERENCES

1. Callery CD, Spiro RH, Strong EW. Changing trends in the management of squamous carcinoma of the tongue. *Am J Surg* 1984; 148: 449-54.

2. Mazon JJ, Crook JM, Marinello G, Walop W, Pierquin B. Prognostic factors of local outcome for T1, T2 carcinomas of oral tongue treated by iridium 192 implantation. *Int J Radiat Oncol Biol Phys* 1990; 19: 281-5.
3. Fu KK, Chan EK, Phillips TL, Ray JW. Time, dose and volume factors in interstitial radium implants of carcinoma of the oral tongue. *Radiology* 1976; 119: 209-13.
4. Decroix Y, Ghossein NA. Experience of the Curie Institute in the treatment of cancer of the mobile tongue. I. Treatment policies and result. *Cancer* 1981; 47: 496-502.
5. Wang CC. Radiotherapeutic management and results of T1N0, T2N0 carcinoma of the oral tongue: evaluation of boost techniques. *Int J Radiat Oncol Biol Phys* 1989; 17: 287-91.
6. Puthawala AA, Syed AMN, Neblett D, McNamara C. The role of afterloading iridium (Ir192) implant in the management of carcinoma of the tongue. *Int J Radiat Oncol Biol Phys* 1981; 7: 407-12.
7. Horiuchi J, Okuyama T, Shibuya H, Takeda M. Results of brachytherapy for cancer of the tongue with special emphasis on local prognosis. *Int J Radiat Oncol Biol Phys* 1982; 8: 829-35.
8. Gerbaulet A, Haic-Meder C, Marsiglia H, et al. The role of brachytherapy in treatment of head and neck cancer: Institute Gustave Roussy experience with 1 140 patients. In: Mould RF, ed. *International brachytherapy-programme and abstracts, 7th International Brachytherapy Working Conference*. Netherlands: Nucletron International BV, 1992: 49-66.
9. Wendt CD, Peters LJ, Delclos L, et al. Primary radiotherapy in the treatment of stage I and stage II oral tongue cancers: importance of the proportion of therapy delivered with interstitial therapy. *Int J Radiat Oncol Biol Phys* 1990; 18: 1287-92.
10. Spiro RH, Strong EW. Epidermoid carcinoma of the mobile tongue: treatment by partial glossectomy alone. *Am J Surg* 1971; 122: 707-10.
11. Jesse RH, Barkley HT, Lindberg RD, Fletcher GH. Cancer of the oral cavity. Is elective neck dissection beneficial? *Am J Surg* 1970; 120: 505-8.
12. Decroix Y, Ghossein NA. Experience of the Curie Institute in treatment of cancer of the mobile tongue II. Management of the neck nodes. *Cancer* 1981; 47: 503-8.
13. Byers RM, Wolf PF, Ballantyne AJ. Rationale for elective modified neck dissection. *Head Neck Surg* 1988; 10: 160-7.
14. Million RR. Elective neck irradiation for T x N0 squamous carcinoma of the oral tongue and floor of mouth. *Cancer* 1974; 34: 149-55.
15. Fletcher GH. Elective irradiation of subclinical disease in cancer of the head and neck. *Cancer* 1972; 29: 1450-4.
16. Leborgne F, Leborgne JH, Barlocchi LA, Ortega B. Elective neck irradiation in the treatment of cancer of the oral tongue. *Int J Radiat Oncol Biol Phys* 1987; 13: 1149-53.
17. Meredith WJ, editor. *Radium dosage: The Manchester System*. Edinburgh: E.&S. Livinstone Ltd, 1947.
18. Pierquin B, Dutreix A, Paine CH, Chassagne D, Marinello G, Ash D. The Paris System in interstitial radiation therapy. *Acta Radiol Oncol* 1978; 17: 33-48.
19. Kaplan EL, Meier P. Nonparametric estimation from incomplete observations. *J Am Stat Assoc* 1958; 53: 457-81.
20. Shah JP, Candela FC, Poddar AK. The patterns of cervical lymph node metastases from squamous carcinoma of the oral cavity. *Cancer* 1990; 66: 109-13.
21. Cunningham MJ, Johnson JT, Myers EN, Schramm VL, Thearle PB. Cervical lymph node metastases after local excision of early squamous cell carcinoma of the oral cavity. *Am J Surg* 1986; 152: 361-6.

22. Spiro RH, Spiro JD, Strong EW. Surgical approach to squamous carcinoma confined to the tongue and the floor of the mouth. *Head Neck Surg* 1986; 9: 27-31.
23. Spiro RH, Huvos AG, Wong GY, Spiro JD, Gnecco CA, Strong EW. Predictive value of tumour thickness in squamous carcinoma confined to the tongue and floor of the mouth. *Am J Surg* 1986; 152: 345-50.
24. Bradfield JS, Scruggs RP. Carcinoma of the mobile tongue: Incidence of cervical metastases in early lesions related to method of primary treatment. *Laryngoscope* 1983; 93: 1332-6.
25. Byers RM. Modified neck dissection. A study of 967 cases from 1970 to 1980. *Am J Surg* 1985; 150: 414-21.
26. Bocca E, Pignataro O, Oldinii C, Cappa C. Functional neck dissection: An evaluation of review of 843 cases. *Laryngoscope* 1984; 94: 942-5.
27. Spiro JD, Spiro RH, Shah JP, Sessions RB, Strong EW. Critical assessment of supraomohyoid neck dissection. *Am J Surg* 1988; 156: 286-9.
28. Spaulding CA, Korb LJ, Constable WC, Cantrell RW, Levine PA. The influence of extent of neck treatment upon control of cervical lymphadenopathy in cancers of the oral tongue. *Int J Radiat Oncol Biol Phys* 1991; 21: 577-81.
29. Korb LJ, Spaulding CA, Constable WC. The role of definitive radiation therapy in squamous cell carcinoma of the oral tongue. *Cancer* 1991; 67: 2733-7.
30. Mendenhall WM, Steed Van Cise W, Bova FJ, Million RR. Analysis of time-dose factors in squamous cell carcinoma of the oral tongue and floor of mouth treated with radiation therapy alone. *Int J Radiat Oncol Biol Phys* 1981; 7: 1005-11.
31. Huang DT, Johnson CR, Schmidt-Ullrich R, Grimes M. Post-operative radiotherapy in head and neck carcinoma with extracapsular lymph node extension and/or positive resection margins: a comparative study. *Int J Radiat Oncol Biol Phys* 1992; 23: 737-42.
32. Day GL, Blot WJ. Second primary tumors in patients with oral cancer. *Cancer* 1992; 70: 14-9.
33. Fijuth J, Mazon JJ, Pechoux CL, et al. Second head and neck cancers following radiation therapy of T1 and T2 cancers of the oral cavity and oropharynx. *Int J Radiat Oncol Biol Phys* 1992; 24: 59-64.