

FROM THE E.N.T.-DEPARTMENT OF SAHLGRENSKA SJUKHUSET, THE LABORATORY OF EXPERIMENTAL BIOLOGY, DEPARTMENT OF ANATOMY, AND THE DEPARTMENT OF ONCOLOGY AND RADIOTHERAPY, UNIVERSITY OF GOTHENBURG, GOTHENBURG, SWEDEN.

BONE CELL VIABILITY AFTER IRRADIATION

An enzyme histochemical study

M. JACOBSSON, P. KÄLEBO, A. TJELLSTRÖM and I. TURESSON

Abstract

Adult rabbits were irradiated to one proximal tibial metaphysis while the contralateral tibia served as a control. Each animal was thus its own control. Single doses of 15, 25 and 40 Gy ^{60}Co were used. The follow-up time was 11 to 22 weeks after irradiation. A histochemical method, recording diaphorase (NADH_2 and NADPH_2) activity in osteocytes, was employed. This method is regarded as superior to conventional histology. No evidence of osteocyte death was found even after 22 weeks following 40 Gy irradiation. This is interpreted as an indication that the osteocytes, which are end stage cells, are relatively radioresistant.

Key words: Radiobiology, cell studies; rabbits, gamma-irradiation, osteocytes, diaphorase activity, viability.

Bone cell viability after irradiation has been investigated by many authors. Different methods have been used, such as radioactive isotope labelling (2, 21), radiography (5, 22), histology (10, 26), histochemical methods (9, 11) and electron microscopy (8, 19), to name but a few. A drawback of many of the most commonly used methods is the difficulty of truly ascertaining if a bone cell is viable or not.

The aim of the present study was to assess irradiation damage to bone tissue with the use of an enzyme histochemical method recording NADH_2 - and NADPH_2 -diaphorase activity of the osteocytes (6) after irradiation doses of 15–40 Gy.

Material and Methods

Animals and anaesthesia. Fifteen adult lop-eared rabbits of both sexes were used. During the irradiation procedure the animals were under general anaesthesia using intramuscular administration of Hypnorm (Mekos, Helsingborg, Sweden) at a dose of 0.7 ml per kg body weight

and hour and intraperitoneal administration of Valium (Roche) at a dose of 0.5 ml per kg body weight.

Irradiation procedure. The room temperature during irradiation was 22°C. The tibia to be irradiated was placed upon a 10 cm thick polystyrene phantom. To minimize the difference in absorbed dose between soft tissue and bone ^{60}Co gamma irradiation was used. Skin source distance was 60 cm and the field size was 7.5×7.5 cm. The dose rate was about 1 Gy per minute. To ensure full build-up a 5 mm thick bolus was applied. The animals were divided into five groups with three animals in each. In group A one animal received 15 Gy, the second 25 Gy and the third animal 40 Gy as a single dose to the medial aspect of one proximal tibial metaphysis. The other tibia served as a control. The same pattern was applied in the other groups (B–E).

Retrieval of bone specimens for analysis. The group A animals were once more anaesthetized with Hypnorm and Valium 11 weeks after irradiation and the skin, fascia and periosteum over the medial aspect of each proximal tibial metaphysis were incised and the cortical bone laid bare. A 15×15 mm large bone specimen was then removed with the use of a saw, using profuse saline irrigation to minimize the heat trauma. Thereafter the animal was sacrificed with an intravenous overdose of nembutal. The retrieved bone specimens were then processed for histology and histochemistry. The animals of the other groups underwent the same procedure but with longer time intervals. The animals of group B were thus sacrificed 14 weeks, those of group C 17 weeks, of group D 20 weeks and of group E 22 weeks after irradiation.

Accepted for publication 21 July 1987.

Histological and histochemical methods. The specimens for histological and histochemical analysis were immediately placed in 10% EDTA of 4°C and pH 6.95 for demineralization. After 10 days the demineralization process was completed. Following decalcification the bone specimens were frozen in isopentane at -140°C and were then sectioned in a cryostat at -20°C . The specimens intended for histology were stained with HTX-eosin and those intended for histochemical analysis stained for NADH₂- and NADPH₂-diaphorase activities (6).

Results

The histological sections showed lamellar bone of normal appearance. No changes were seen in the morphology of the bone architecture and the lamellae were intact. The number of filled osteocyte lacunae did not differ between test and control specimen in any of the animals investigated at any dose level or at any of the follow-up times used in the study. The histochemical analysis of the same bone specimens demonstrated strong activity of oxidative enzyme activities, thus indicating viable osteocytes.

Discussion

The present results indicate that the osteocytes in mature bone tissue can sustain high doses of ionizing irradiation without cell death. Conventional histological investigation of bone cell viability as evidenced by empty lacunae (dead cells) or filled lacunae (living cells) has been regarded as uncertain (12). KENZORA et coll. (18) demonstrated the presence of filled lacunae several days after osteocyte necrosis confirmed by H³-cytidine autoradiography. The same authors could also prove that empty osteocyte lacunae may be due to artifacts accompanying the fixation and processing of the bone tissue specimen. Several other authors support the view of histology as an uncertain indicator of bone cell viability (7, 20). The present method has been regarded as superior to conventional bone histology in the evaluation of bone cell viability (1). The diaphorase enzymes, NADH₂ and NADPH₂, are strictly intracellular and produced by metabolically active cells. Presence of diaphorase enzymes will thus indicate cell viability.

The relative radioresistance of the mature bone rests on the concept of the osteocyte as a fixed post mitotic cell, incapable of further cell division (24, 25). Bone viability after irradiation has been demonstrated by other authors (3, 23). In a vital microscopic investigation on mature bone tissue in the rabbit JACOBSSON et coll. (14) found no evidence of bone necrosis after up to 40 Gy ⁶⁰Co irradiation in single doses with follow-up times up to several years. On the other hand, evidence of retardation of bone healing has been brought forth in several studies (15–17). The bone cells responsible for bone formation, namely the osteoblasts, are less differentiated (reversible post mitotic

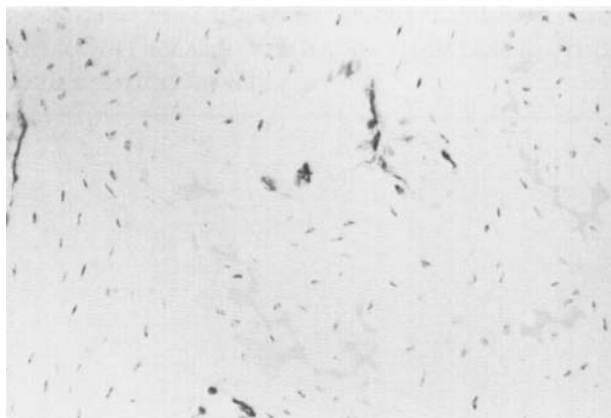


Figure. Histologic section from bone tissue irradiated to 40 Gy 14 weeks before sacrifice. Staining with NADH₂. The osteocyte lacunae show oxidative enzyme activity, indicating cell viability.

cells) than the osteocytes. The osteoblast precursors, called pre-osteoblasts, are even less differentiated (vegetative intermitotic cells) (25). BERGONIE & TRIBONDEAU in 1906 postulated that the higher the proliferation rate of a cell the higher the radiosensitivity and vice versa. In the light of the present results this seems to be the case regarding the bone cells.

The mature bone cells, the osteocytes, are highly differentiated cells (fixed post mitotic cells) incapable of further cell division and proliferation. The osteocytes appear to be relatively radioresistant as no evidence of cell necrosis was found after up to 40 Gy single dose ⁶⁰Co irradiation up to 22 weeks following irradiation.

Request for reprints: Dr. Magnus Jacobsson, E.N.T.-Department, Sahlgrenska sjukhuset, S-41345 Göteborg, Sweden.

REFERENCES

1. ALBREKTSSON T., BRÄNEMARK P.-I., ERIKSSON A. and LINDSTRÖM J.: The preformed autologous bone graft. An experimental study in the rabbit. *Scand. J. Plast. Reconstr. Surg.* 12 (1978), 215.
2. ANDERSSON N. D., COLYER R. A. and RILEY L. H.: Skeletal changes during prolonged external irradiation. Alterations in marrow, growth plate and osteoclast populations. *The Johns Hopkins Med. J.* 145 (1979), 73.
3. BELL E. G., MCAFEE J. G. and CONSTABLE W. C.: Local radiation damage to bone and marrow demonstrated by radioisotopic imaging. *Radiology* 92 (1969), 1083.
4. BERGONIE J. et TRIBONDEAU L.: Interprétation de quelques résultats de la radiothérapie et essai de fixation d'une technique rationnelle. *C.R. Acad. Sci.* 143 (1906), 983.
5. BURGNER F. A., KING M. A. and WEBER D. A.: Korrelation zwischen radiologischen, szintigraphischen und histologischen Veränderungen im Knochen beim Kaninchen nach Bestrahlung mit Einzel- und Fraktionierter-Dosis. *Fortschr. Röntgenstr.* 130 (1979), 366.
6. CHAYEN J., BITENSKY L. and BUTCHER R.: *Practical histochemistry.* Wiley, London 1973.
7. DANCKWARDT-LILLIESTRÖM G.: Reaming of the medullary cavity and its effects on diaphyseal bone. A fluorochromic,

- microangiographic and histologic study on the rabbit tibia and dog femur. *Acta Orthop. Scand. Suppl.* 128, 1969.
8. DROUET J., DELOINCE R. and BARON R.: Etude ultrastructurale de la réaction périostée au cours des fractures diaphysaires chez des souris exposées à une radiation X. *Médecine et armées* 2 (1974), 427.
 9. ENGSTRÖM H., TURESSON I. and WALDENSTRÖM J.: The effects of 50 kV X-ray irradiation on the alkaline phosphatase activity of growing rat bone. *Int. J. Radiat. Biol.* 40 (1981), 659.
 10. EWING J.: Radiation Osteitis. *Acta Radiol.* 6 (1926), 399.
 11. FURSTMAN L. L.: Effects of radiation on bone. *J. Dent. Res.* 51 (1972), 596.
 12. JACOBSSON M.: On bone behaviour after irradiation. Thesis, University of Gothenburg, Sweden 1985.
 13. — ALBREKTSSON T. and TURESSON I.: Dynamics of irradiation injury to bone tissue. A vital microscopic investigation. *Acta Radiol. Oncol.* 24 (1985), 343.
 14. — JÖNSSON A., ALBREKTSSON T. and TURESSON I.: Dose response for bone regeneration after single doses of Co-60 irradiation. *Int. J. Radiol. Oncol. Biol. Phys.* 11 (1985), 1963.
 15. — — — Alterations in bone regenerative capacity after low irradiation doses. A quantitative study. *Scand. J. Plast. Reconstr. Surg.* 19 (1985), 231.
 16. — — — Short- and long-term effects of irradiation on bone regeneration. *Plast. Reconstr. Surg.* 76 (1985), 841.
 17. — KÄLEBO P., ALBREKTSSON T. and TURESSON I.: Provoked repetitive healing of mature bone tissue following irradiation. A quantitative study. *Acta Radiol. Oncol.* 25 (1986), 57.
 18. KENZORA J. E., STEELE R. E., YOSIPOVITCH Z. H. and GLIMCHER H. J.: Experimental osteonecrosis of the femoral head in adult rabbits. *Clin. Orthop.* 130 (1978), 8.
 19. MARQUART K.-H.: Frühe Ultrastrukturveränderungen in der Tibiametaphyse der Maus nach Inkorporation von Ra-244. *Verh. Dtsch Ges. Pathol.* 57 (1973), 466.
 20. MOLANDER H.: Revascularization and healing of stabilized non-vital cortical fragments. Studies in the rabbit tibia. Thesis. University of Uppsala, Sweden 1981.
 21. RISSANEN P., ROKKANEN P. and PAATSAMA S.: The effect of Co-60 irradiation on bone in dogs. Part I. Mature bone. *Strahlentherapie* 137 (1969), 162.
 22. ROHRER M. D., KIRCOS L. T., THRALL J. H., KIM Y. and FAYOS J. V.: Evaluation of irradiated mandibles using emission tomography, bone scans and radiography. *J. Dent. Res.* 59 (1980), 2032.
 23. RUBIN P.: The radiographic expression of radiotherapeutic injury. An overview. *Seminars in Roentgenology* 9 (1974), 5.
 24. — and CASARETT G. W.: *Clinical Radiation Pathology*, Vol I and II. W. B. Saunders Company, Philadelphia, London, Toronto 1968.
 25. TONNA E. A.: Bone tracers. Cell and tissue level techniques. *In: Skeletal research. An experimental approach*, p. 487. Edited by D. J. Simmons and A. S. Kunin. Academic Press, New York, San Francisco, London 1979.
 26. WARREN S.: Skeletal and tissue lesions resulting from exposure to radium and fission products. *Ann. Clin. Lab. Sci.* 5 (1975), 75.