

FROM THE DEPARTMENT OF GYNECOLOGY (DIRECTOR: PROF. H. L. KOTTMEIER),
AND THE SECTION OF DIAGNOSTIC RADIOLOGY (DIRECTOR: C. LAGERGREN), RADIUM-
HEMMET, STOCKHOLM, SWEDEN.

TRANSVERSE AXIAL TOMOGRAPHY AS AN ADJUNCT IN RADIOTHERAPY OF CARCINOMA OF THE UTERINE CERVIX

by

INGEMAR JOELSSON

An appraisal of the dynamic topographic relationship of the pelvic visceral organs has been the concern of the radiotherapist in the treatment of carcinoma of the uterine cervix. Attempts have been made to assess the variability of position as well as to delineate in each patient the distance between the tumor requiring a cancerocidal dose of radiation and the healthy tissue that should not be compromised. Investigations have not yielded useful results, mainly because of the difficulty in appraising the solid geometry of the pelvic content from roentgenograms taken in perpendicular planes or produced by the focus shift method. The pattern in the films formed by the anatomic structures of interest is frequently obscured by adjacent organs. It was therefore thought that the anatomic relation between the uterine cervix, the uterine bladder and the rectum might be individually determined by means of transverse tomography by the method described by TAKAHASHI (1965, 1969).

This work was supported by grants from the Cancer Society of Stockholm and the King Gustaf V Jubilee Fund. Submitted for publication 30 June 1970.

Material and Methods. Ten patients with carcinoma of the uterine cervix, stage I—IIb, were studied. The patients were first examined with a. p. and cross-table lateral roentgenograms and radiopaque centimeter scales were positioned parallel to the longitudinal axis of the body. As the next procedure, the patients were examined by transverse axial tomography (Toshiba, Model CS-BC) with a metal ring sutured about the portio of the cervix; a metal cylinder, 6 mm in diameter, was at the same time inserted into the cervical canal. All patients received 20 ml Urografin instilled into the emptied bladder through a catheter after 20 ml barium emulsion had been introduced into the rectum. If the examination lasted more than 30 minutes the bladder was re-emptied and another injection of Urografin made. Consecutive body sections, 1 cm apart, were exposed, starting 3 cm caudal to the cranial border of the symphysis pubis. The last section was exposed 7 cm cephalad to the cranial border of the symphysis pubis.

The tomograms were taken with a constant magnification factor (M) of 1.33 and the series of photographs were redrawn to true size by means of an optical system. The distance between the center of the cervical cylinder and the closest part of the urinary bladder or rectum was measured in those sections where the outlines were discernible.

It is appreciated that in the tomographic method the thickness of the layer (t) depicted is a function of the maximally tolerated blur (B_m) according to the equation:

$$t = B_m \times \cot \theta \times \frac{1}{M}$$

where θ is the angle between the central roentgen ray and the normal to the tomographic plane, in this case 70° (MEREDITH & MASSEY 1968). The acceptance of 1.5 mm of blur means the representation in one film of a 0.4 mm thick tissue layer; in practice, however, the layer is somewhat thicker due to the effect of the screens and to other factors although the limits are still adequate for the validity of the measurements in this investigation.

Results

Rectum. The distance between the center of the cylinder in the cervical canal and the closest contour of the rectum varied considerably in the tomographic section in this series of patients (Table 1). In one of the patients (aged 49, stage Ib carcinoma) the distance was only 9 mm and in another (aged 51, stage IIa carcinoma) the distance was 34 mm. The transverse sections that were suitable for measurements of the cervical-rectal distance lay in a region between 1 and 6 cm cephalad to the upper border of the symphysis pubis. The maximal dif-

Table 1

Distance in mm between the center of the cervical canal and the closest part of the contrast-coated rectal mucosa, measured in transverse body sections from 1 to 6 cm cephalad to the cranial border of the symphysis pubis

Patient No.	Cephalad to the cranial border of the symphysis pubis					
	1 cm	2 cm	3 cm	4 cm	5 cm	6 cm
1		16	19	16		
2			16	14		
3		11	12			
4				34		14
5		24	34	32		
6	18	15				
7					26	21
8				16	9	
9		21	22	12		
10			21	17		

ference in measured distance between the center of the cervical canal and the bowel wall, comparing one section with the next consecutive one, was 10 mm.

The cervical-rectal distance as well as the cervical-rectal topography varied. The rectum was usually located on the right side of the genital canal in the transverse sections caudal to the portio (Figs 1 and 2). The distance between the center of the cervix and the rectum was at a minimum in the sections taken through that part of the uterine cervix between the portio and the vault of the posterior fornix. The rectum in this region was consistently located directly posterior to the cervix and in 5 of the 10 patients the bowel here changed from a right-sided to a left-sided position relative to the genital canal (Figs 3 and 4). The bowel adopted a left-sided position in relation to the cervical canal from the level of the cranial part of the posterior vaginal fornix and in a cephalad direction (Fig. 5).

Bladder. The distance between the center of the cervical canal and the closest part of the urinary bladder was measurable in the transverse sections taken over a 7 cm long region in the cephalad direction starting at the cranial border of the symphysis pubis (Table 2). The range of distances between the structures was 14 to 32 mm. The maximal variation between the consecutive sections in one patient was 16 mm. In 3 out of 10 patients the lateral border of the bladder projected in a dorsal direction more than a centimeter posterior to the cervical canal. An example of this appears in Fig. 1.

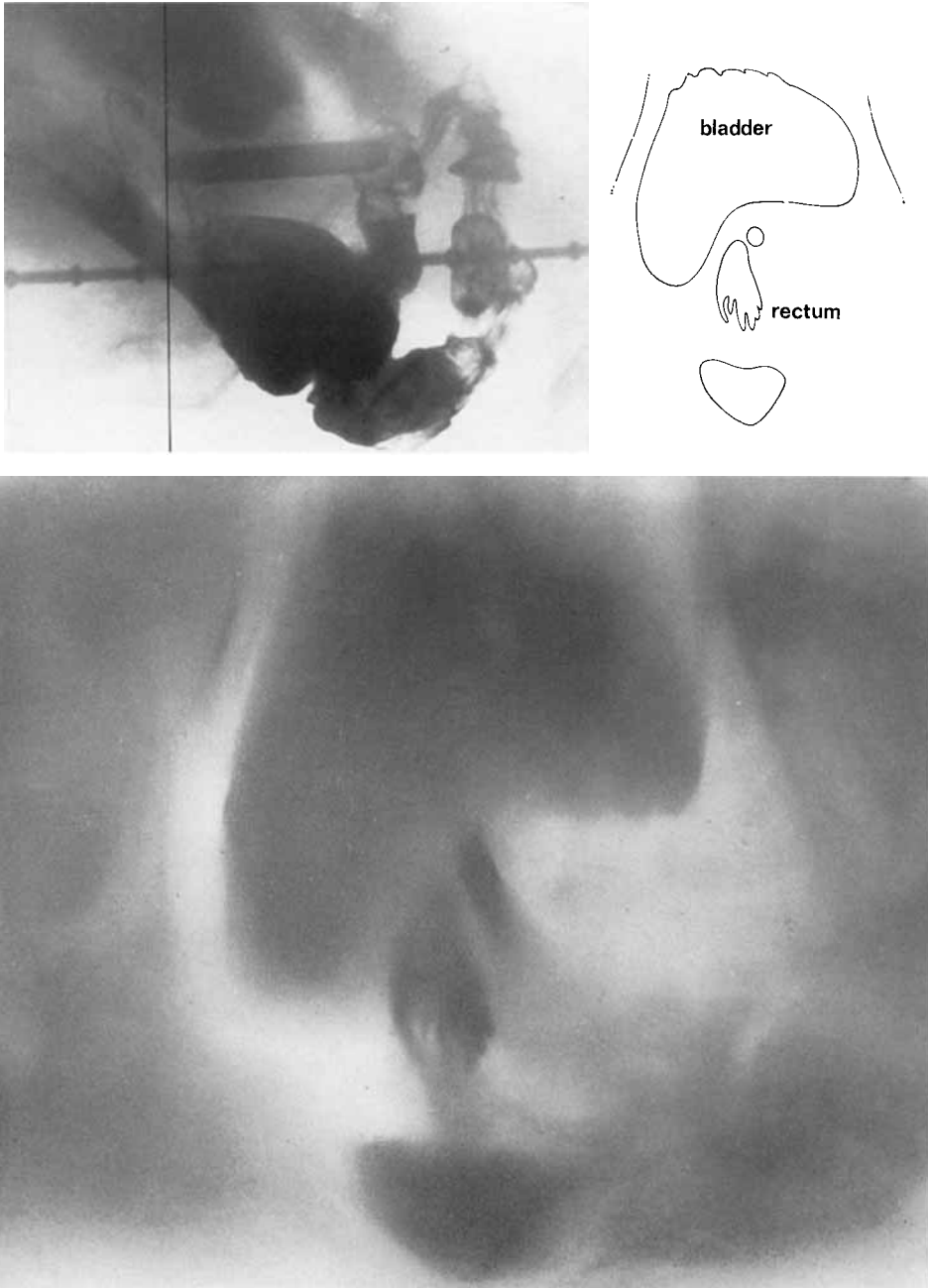


Fig. 1. Transverse body section through the upper part of the vagina caudal to the portio. The position of the plane is indicated in the lateral roentgenogram.

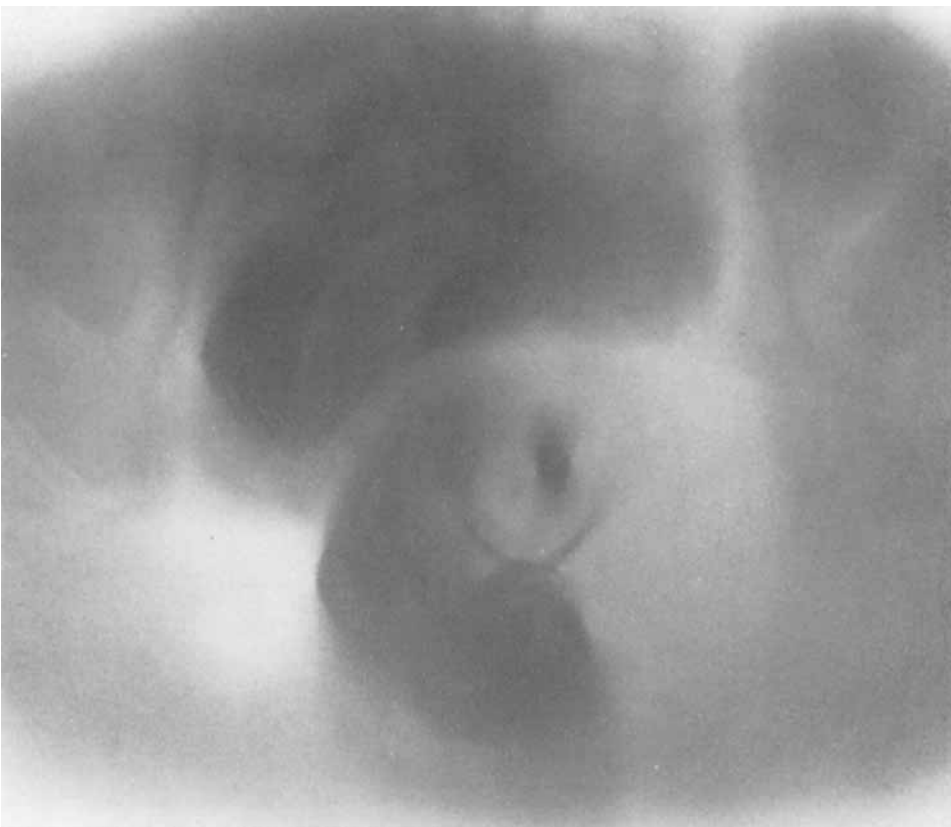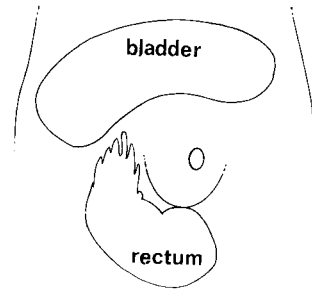
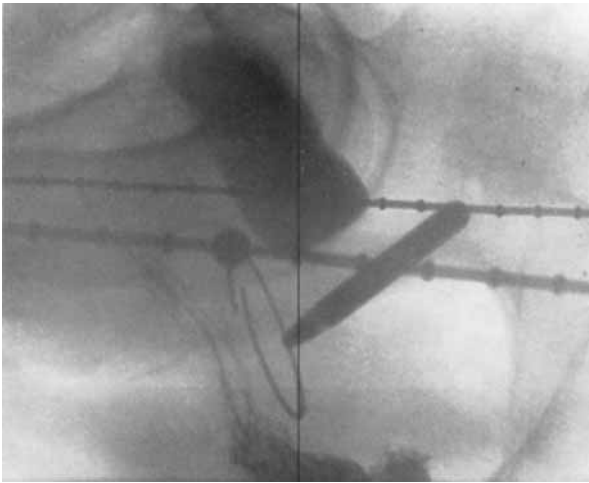


Fig. 2. Transverse body section through the upper part of the vagina at the level of the portio.

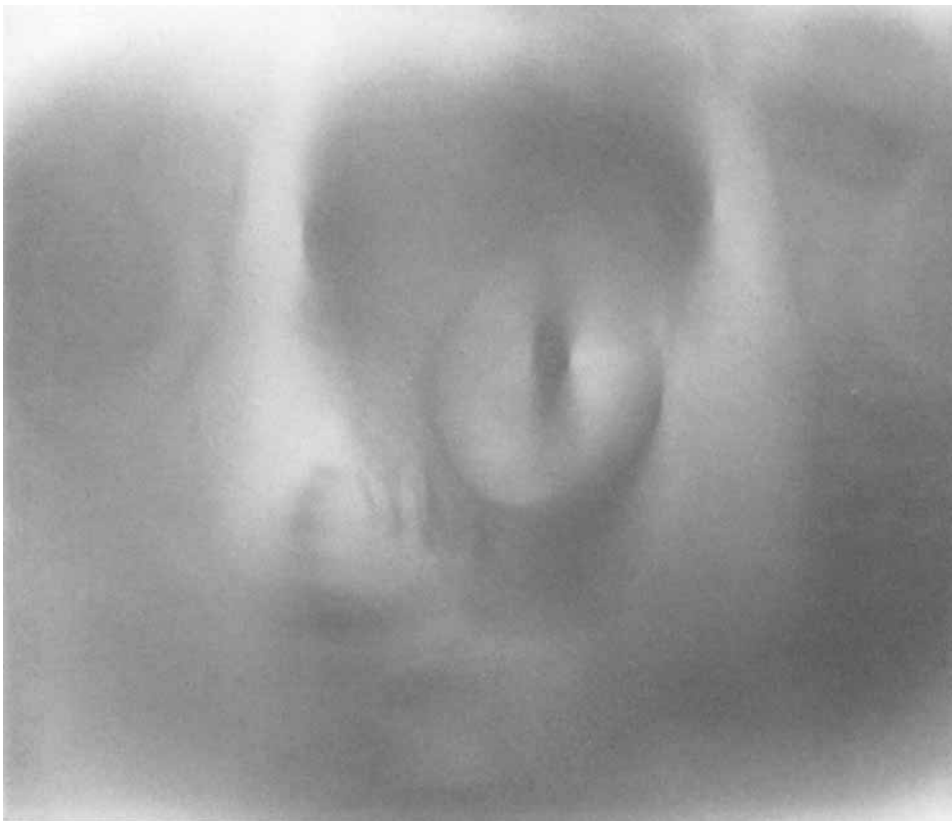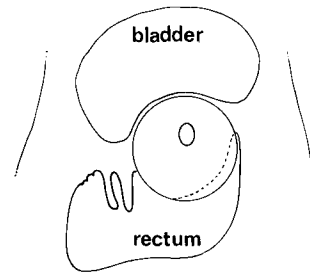
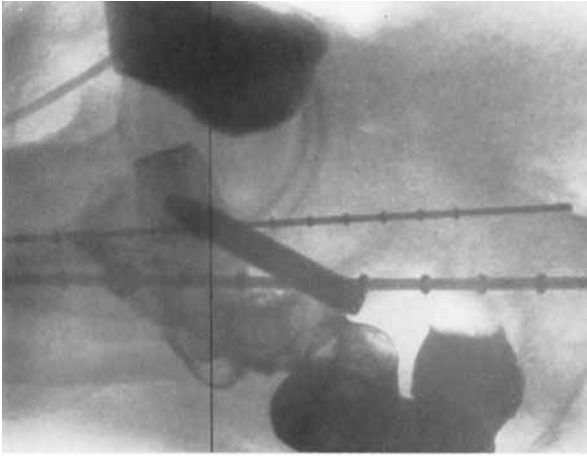


Fig. 3. Transverse tomogram through the distal part of the uterine cervix.

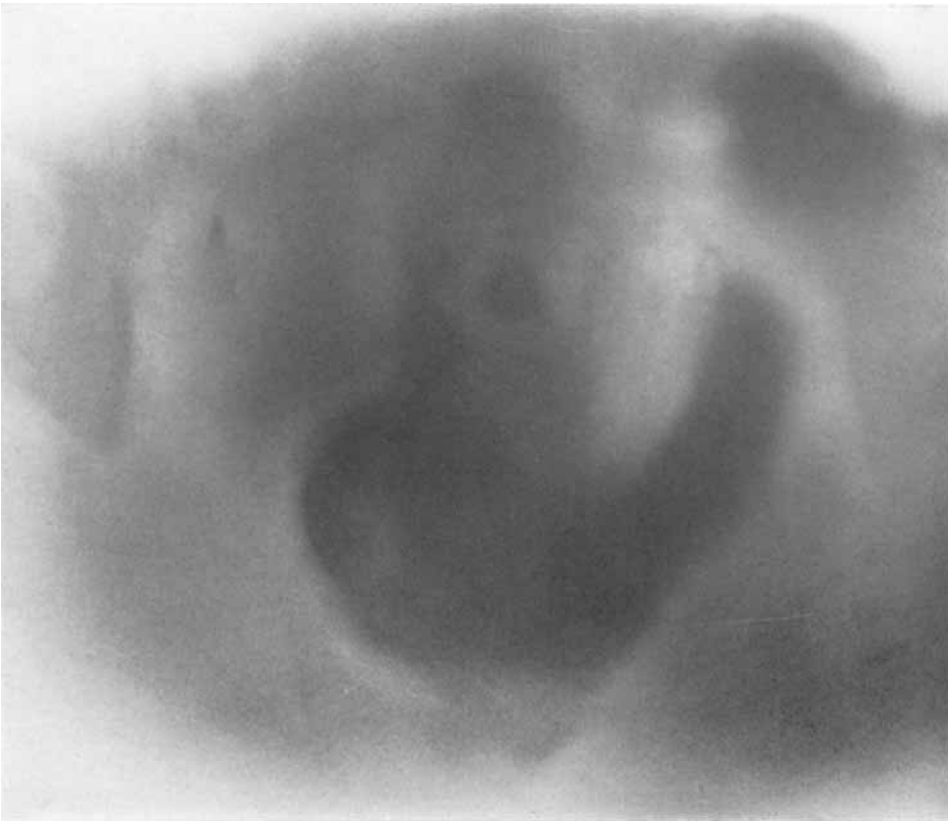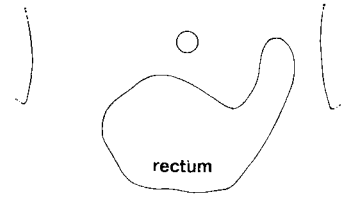
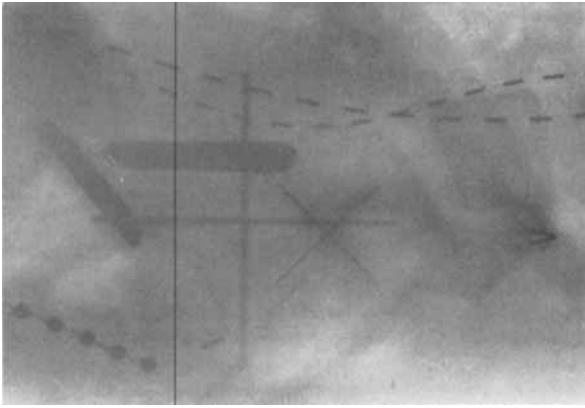


Fig. 4. Tomogram through the uterine cervix caudal to the dome of the posterior vaginal fornix.

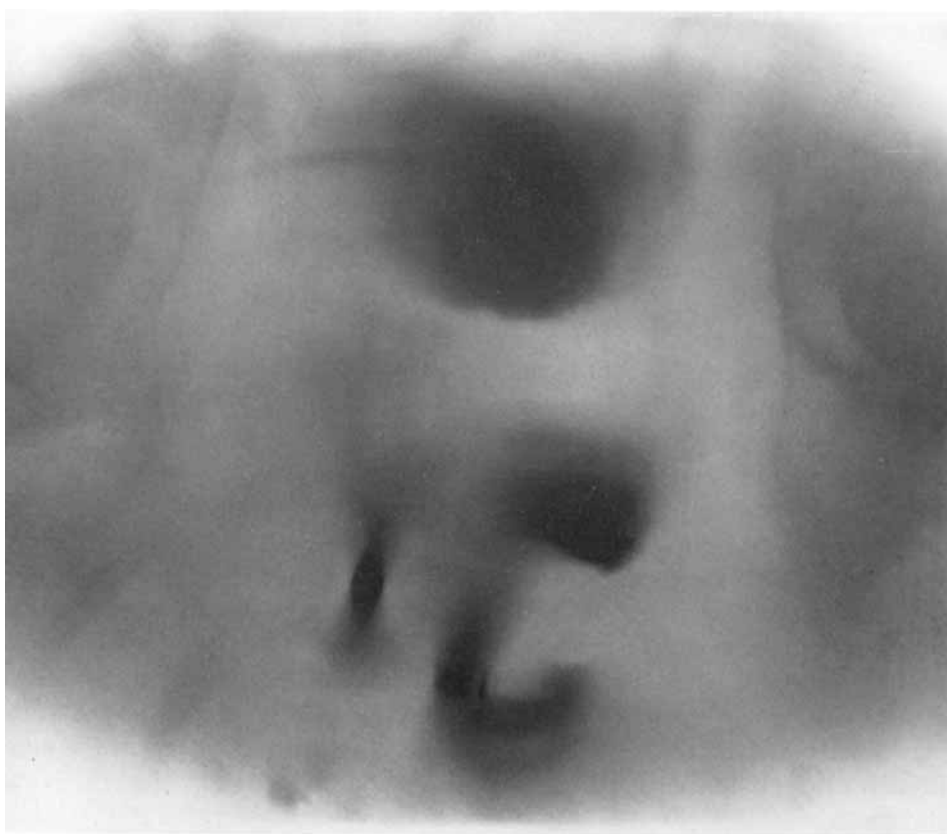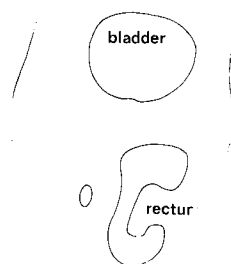
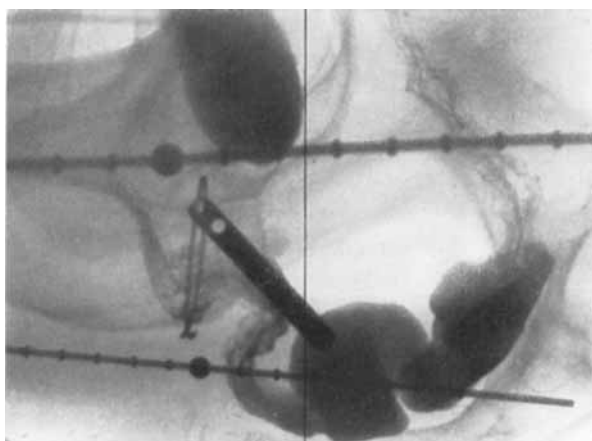


Fig. 5. Tomographic section through the isthmus of the uterus.

Table 2

Distance in mm between the center of the cervical canal and the closest part of the contrast-coated bladder mucosa, measured in transverse body sections from 0 to 7 cm cephalad to the symphysis pubis

Patient No.	Cephalad to the cranial border of the symphysis pubis							
	0 cm	1 cm	2 cm	3 cm	4 cm	5 cm	6 cm	7 cm
1				14	23			
2				14	21			
3		21	14	16	18			
4					15			
5			22	24				
6	16	27	11					
7						30	24	20
8					24	20	25	
9			27	25	32			
10				24	21	18		

Discussion

Irrespective of the therapeutic modality, the significance of determining the anatomic relationship between the uterine cervix and the distal portion of the large intestine as well as the posterior wall of the urinary bladder in each patient is obvious to the radiotherapist involved in the coordination between intracavitary and external radiation treatment in gynecology.

Several years ago the patients at Radiumhemmet were examined with stereoscopic roentgenograms during the intracavitary treatment courses. The information that was needed for estimation of the radiation dose at the posterior wall of the bladder or at the anterior wall of the rectum was, however, not provided by this method. Although other procedures were tried, for example three-dimensional reconstruction techniques: the computation of bladder and rectal doses from direct measurements of dose rates became the method of choice in clinical routine. Measured dose-rates at the posterior wall of the bladder, along the urethra and at the anterior wall of the rectum also serve in the detailed planning of the combined intracavitary and external therapy. The decision whether or not a shielding block should be used is for example made from a consideration of the obtained measurement values. The proper interpretation of these data is that the dose values represent doses of clinical significance in the immediate periphery of the uterine cervix, or, viewed another way, at the outer contour of the tumor. It has been observed in the present study that the bowel changes from a right-sided to a left-sided position in the pelvis in the region of the posterior fornix of the vagina. The tomograms demonstrated that the rectum

occupies a considerable part of the pelvis directly posterior to the uterine cervix at this level. In some of these tomographic sections, the breadth of the rectum may be 10 cm or more. The same is true regarding the bladder. These anatomic facts play an important role for the understanding of the occurrence of complications produced by the primary radiotherapy. It would therefore seem reasonable that the use of routine transverse axial tomography could be of help in treatment planning and coordination of therapy in carcinoma of the uterine cervix. The method would especially facilitate the correct placement of the shielding blocks in the external radiation beams.

Figures have been given in this presentation regarding the distance between the center of the cervical canal and the viscera, as determined from the margin of the contrast-coated mucous membranes of the urinary bladder and the rectum. It should be remembered, however, that these figures are only indicative of the close relationship between the structures portrayed.

The method of transverse axial tomography carries with it inherent sources of errors. On the one hand, the tomographic motion blur of details outside the tomographic layer may simulate closer spatial relationships between two structures than exists in reality. On the other hand all distances measured on the tomograms lie in transverse planes. If the true minimal distances between the structures form an angle with the transverse plane, the measured distances will necessarily be exaggerated. Since the axes of the genital canal and the distal colon are seldom parallel to the long axis of the patient, the true distance between the cervix and the rectum are usually less than those measured.

A difficulty in transverse axial tomography lies in the uncertainty of translation from the tomographic layer in a cranio-caudal direction of the body to the point of its intersection with the anterior body contour. The cranial border of the symphysis pubis is often used as an anatomic reference in clinical routine, but it is seldom possible to define it with an uncertainty under ± 0.5 cm. This is due to the rounded shape of the bone and to the variable, but usually thick, layer of subcutaneous fat over the symphysis of the female. Furthermore, the variation in inclination of the pelvis in supine position causes an uncertainty regarding the intersection with a central or posteriorly located pelvic structure of a strictly transverse plane, the position of which is determined by its relation to the anterior body surface. A. p. with or without cross-table lateral roentgenograms are therefore needed together with the tomogram for the precise indication of the position of the tomographic layer.

Conclusion

Transverse axial tomography of the pelvic region revealed that the rectum usually occupied a considerable part of the pelvis directly posterior to the uterine

cervix; the distance between the rectum and the center of the cervical canal was minimal in the region of the posterior fornix of the vagina. The urinary bladder was observed to rest around the anterior aspect of the cervix, with the lateral parts of the bladder extending even posterior to the level of the cervical canal.

Acknowledgement

The author wishes to thank Professor Paul Edholm for valuable help and discussions.

SUMMARY

Transverse axial tomography has been used in a series of patients with carcinoma of the uterine cervix, stage I—IIb. The wide variability in the topographic relationship between the uterine cervix, the urinary bladder and the rectum was confirmed. It is suggested that the method could be a valuable addition to the planning of radiotherapy in carcinoma of the uterine cervix.

ZUSAMMENFASSUNG

In einer Serie von Patienten mit einem Carcinom des Uterus-Halses, Stadium I—IIb, wurde eine transversale Axial-Tomographie ausgeführt. Die grosse Variabilität der topographischen Beziehung zwischen Cervix uteri, Blase und Rectum wurde bestätigt. Es liegt auf der Hand, dass diese Methode eine wertvolle Erweiterung bei der Planung der Radiotherapie des Carcinoms des Uterus-Halses sein kann.

RÉSUMÉ

L'auteur a utilisé la tomographie axiale transverse chez un série de malades atteintes de cancer du col de l'utérus aux stades I—IIb. La grande variabilité des rapports topographiques entre le col utérin, la vessie et le rectum est confirmée. L'auteur pense que cette méthode pourrait être un complément intéressant pour établir le plan de radiothérapie dans le cancer du col utérin.

REFERENCES

- MEREDITH W. J. and MASSEY J. B.: *Fundamental physics of radiology*. John Wright & Sons, Bristol 1968.
- TAKAHASHI S.: *Conformation radiotherapy. Rotation techniques as applied to radiography and radiotherapy of cancer*. Acta radiol. (1965) Suppl. No. 242.
- *An atlas of axial transversal tomography and its clinical application*. Springer Verlag, Berlin 1969.