

## FIELD CONTROL IN ROENTGEN THERAPY WITH A 5 MeV LINEAR ACCELERATOR BY MEANS OF TELEVISION

by

ROLAND MALVÉN, BENGT ROSENGREN and HENRY WALLMAN

Field control of direct roentgen irradiation from a 30 MeV betatron and direct gamma irradiation from a cobalt 60 unit were described in two previous publications (BENNER, ROSENGREN, WALLMAN & NETTELAND 1962 and MALVÉN, ROSENGREN & WALLMAN 1965). The advantages of continuous and direct monitoring, especially in connection with the use of small fields, were pointed out in these articles. The technical difficulties involved in obtaining adequate contrast and detail were also discussed.

One of the therapeutically important advantages of high-voltage radiation is the small difference in absorption between various tissues; this, however, necessarily implies low contrast. The possibility of contrast enhancement afforded by television techniques, combined with the use of either gold as an indicator, or air as negative contrast, makes it possible to achieve satisfactory reproduction.

---

Submitted for publication 8 August 1967.

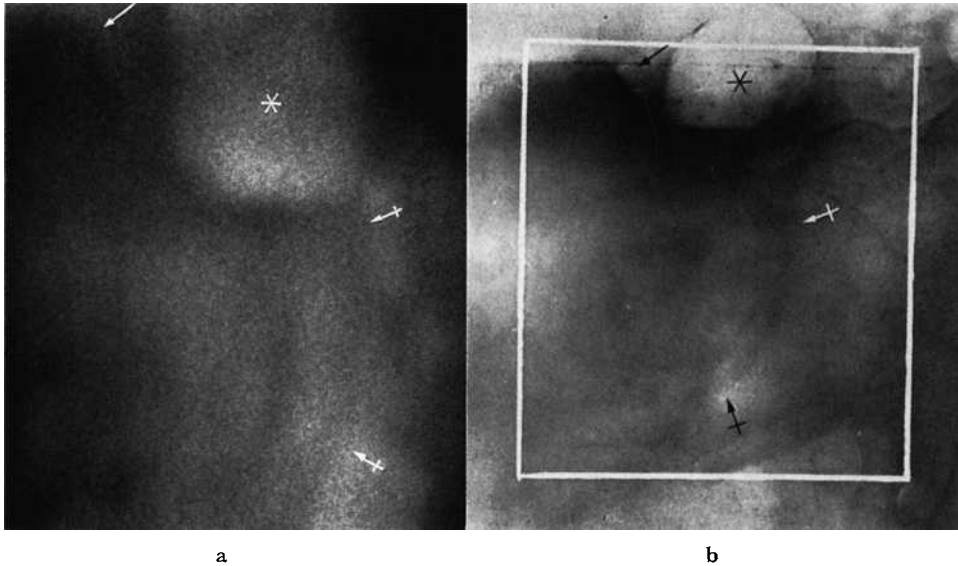


Fig. 1. Corresponding pair of accelerator-television image (a) and roentgenogram obtained with 125 kV (b) from a patient with bladder insufflated with  $\text{CO}_2$  (contrast level at \*). Symphysis pubis ( $\rightarrow$ ), hip joint ( $\leftarrow$ ). Image (a) corresponds to area outlined in (b).

In the most recent paper (MALVÉN et coll. 1965) this contrast enhancement was exemplified by photographs taken from a television monitor screen during treatment of a gynecologic carcinoma, with metastases in the pelvic wall marked by gold indicators. Other examples included insufflation of gas into the bladder for a brief localization preceding the treatment itself (which should be given with an empty bladder), and use of the air present in the upper respiratory tract for observation of the laryngeal or pharyngeal tumours during treatment.

The technique was described in detail in the first paper (BENNER et coll.). Mention was made in the second paper (MALVÉN et coll.) of the modifications arising from the use of a cobalt unit.

In the present contribution, the use of this technique in connection with therapy with a 5 MeV linear accelerator will be described.

The radiation qualities with a gamma unit and a 5 MeV linear accelerator are therapeutically equivalent, with a somewhat larger depth dose with the latter. The penumbra is, however, considerably smaller in the case of the linear accelerator, in view of the fact that the focus is about 4 mm in diameter whereas the radiation source in our cobalt unit is 20 mm  $\times$  20 mm

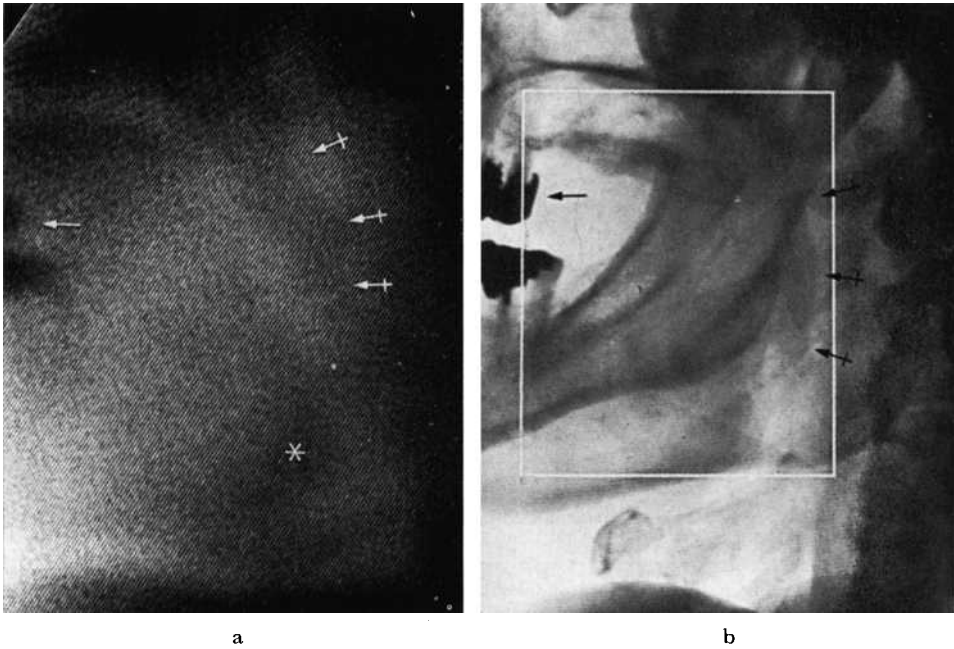


Fig. 2. Corresponding pair of accelerator-television image (a) and roentgenogram obtained with 125 kV (b) from a patient with tonsil tumour. Filled teeth ( $\rightarrow$ ), soft palate ( $\leftrightarrow$ ), mandible (\*).

in size. Better definition but somewhat poorer contrast should therefore be obtained in television monitoring with a linear accelerator in place of a cobalt unit.

The same technical equipment for field control in connection with these two therapeutic units was employed. Definition was better with the linear accelerator, although the improvement was not so great as could have been expected from a comparison of the focus sizes. The contrast was, as expected, somewhat poorer with the linear accelerator than with the cobalt unit.

A bladder in which gas (carbon dioxide) was insufflated previous to treatment is well outlined in Fig. 1a; an indicator roentgenogram (125 kV) of the same patient in the same projection, is reproduced in Fig. 1b. The negative contrast in the gas-filled part of the bladder and in the rectum is satisfactory in the high-voltage roentgen television image. The definition and the contrast are of course considerably poorer than in the roentgen film.

A corresponding pair of images from a patient with tonsil tumour treated with the linear accelerator are represented in Fig. 2. The air is visible to

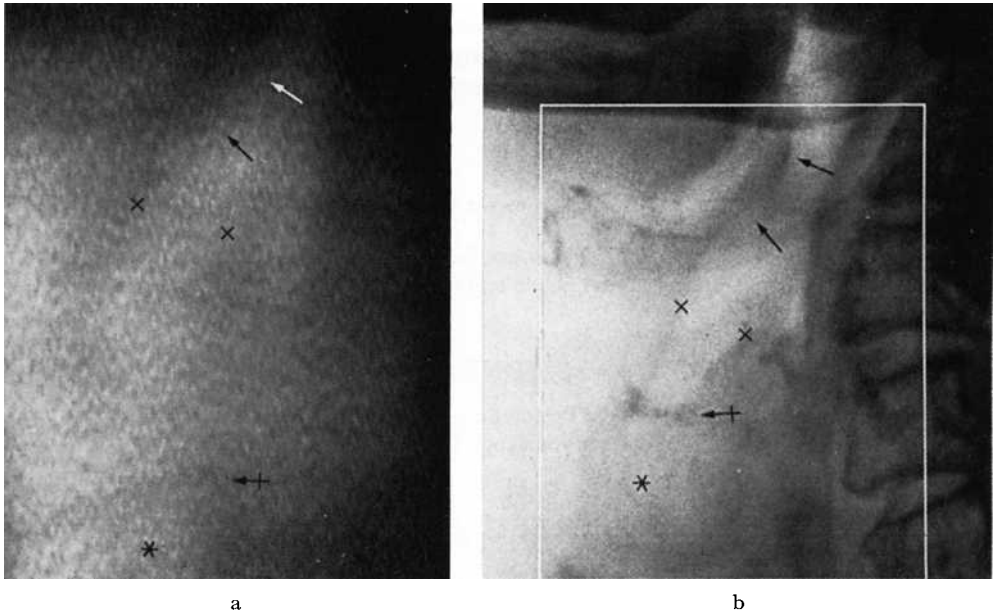


Fig. 3. Corresponding accelerator-television image (a) and roentgenogram (b) from a patient with laryngeal carcinoma. Epiglottis ( $\rightarrow$ ), introitus laryngis ( $\times$ ), vocal cord level ( $+\rightarrow$ ), trachea (\*).

approximately the same extent in the two images. Definition is however less good in the accelerator-television image although the anatomical details are sufficient to permit an orientation. It is also apparent from the television image that the medulla is not being irradiated.

A similar comparison was made in a case of laryngeal carcinoma, as demonstrated in Fig. 3.

### Conclusion

The amount of detail in the high-voltage roentgen-television image cannot of course be compared with that in conventional roentgen films owing to the lower contrast produced by the high-energy radiation. Another reason is that roentgenograms are usually obtained in projections selected in the manner most favourable from the diagnostic point of view. On the other hand, the megavolt roentgen-television images are based upon projections determined by the location of the field of treatment, these in turn being determined by considerations of optimal dose distribution. The megavolt

images can, however, provide the radiation therapist with good localization of the field of treatment, and increasing experience in the interpretation of the appearances arising from the projections occurring in therapy will add considerably to their value.

### SUMMARY

A special system for field control in linear-accelerator therapy is described and exemplified with treatments of the head, neck, and pelvic regions.

### ZUSAMMENFASSUNG

Ein neues Feldkontrollsystem für die Bestrahlung mit linearen Schleudern wird beschrieben und mit Beispielen für die Behandlung von Kopf, Hals und Becken illustriert.

### RÉSUMÉ

Les auteurs décrivent un système spécial de localisateur de champ pour le traitement par accélérateur linéaire et donnent des exemples de traitements des régions de la tête, du cou et du bassin.

### REFERENCES

- BENNER S., ROSENGREN B., WALLMAN H. and NETTELAND O.: Television monitoring of a 30 MV X-ray beam. *Phys. in Med. Biol.* 7 (1962), 29.
- MALVÉN R., ROSENGREN B. and WALLMAN H.: Field control of telecobalt therapy by gamma-ray television. *Acta radiol. Ther. Phys. Biol.* 3 (1965), 425.