

INFLUENCE OF TOTAL DOSE AND OF AGE ON  
EFFECTS OF PROTON IRRADIATION OF SPINAL  
CORDS OF YOUNG RATS

by

SHIRLEY ANN GILMORE

The central nervous system responds to ionizing radiation in a manner which varies with respect to the age or the developmental stage of the organism at the time of irradiation. The prenatal nervous system can be severely damaged by rather small amounts of ionizing radiation. The adult nervous system, on the other hand, can withstand larger quantities of radiation but is not totally resistant to such insults. Within this range of markedly different degrees of radiosusceptibility lies the neonatal or young nervous system which has not been investigated as thoroughly.

As early as 1902, SHOLTZ showed that hindlimb paralysis occurred after irradiating the nervous system of young rabbits, and in 1906 FÖSTERLING advised the use of caution in exposing children to ionizing radiation. In spite of the early beginning of this field of investigation little detailed information is available because few studies reporting all information necessary for evaluating results have appeared in the literature. The only recent, systematic work concerned with the effects of different amounts of radiation administered to

---

Submitted for publication 26 January 1965.

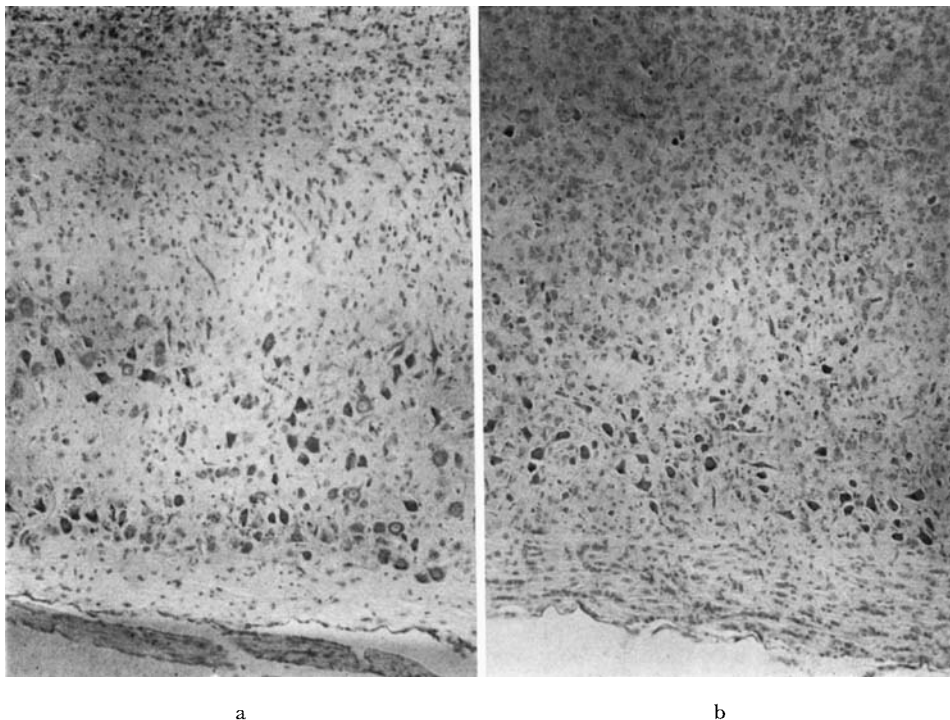


Fig. 1. a) Lumbar spinal cord of rat irradiated with 12 krad when 4 days old and killed 13 days later. Decrease in number of neuroglia, being especially evident in the white matter. Abundant, apparently normal neurons. b) Normal region above the irradiated area of spinal cord shown in (a). Cresyl echt violet stain.  $\times 90$ .

different age groups is that of YAMAZAKI et coll. (1960) who studied the responses of rats receiving 125 R to 1 000 R of roentgen rays to the head when 8 hours to 15 days of age. This investigation showed that the majority of rats receiving 300 R or more, when less than five days of age, developed abnormal neurologic signs, as compared with only 15 % of rats irradiated after five days of age. Microscopic examination of the brains from these same animals (CLEMENTE et coll. 1960) showed a correlation between the incidence of neurologic abnormalities and the neuropathology.

The present investigation is one of a series of studies of microscopically noted changes and neurologic abnormalities resulting from irradiation of the spinal cords of neonatal and young rats (GILMORE 1963a, 1963b, 1964). Its purpose is to determine both neurologic and neuropathologic changes resulting from the administration of different amounts of high energy protons to spinal cords of rats from 3 to 16 days of age.

**Table**

*Summary of results obtained after proton irradiation of the lumbar spinal cords of neonatal rats —  
(1) Transient period (ca. one week) of slight neurologic change*

Total amount of radiation krad	Dose rate rad/min	Animals in group	Age at time of irradiation, days	Animals with neurol. changes	Onset of neurol. changes at days postirrad.	Animals remaining normal	Animals dead prior to neurol. changes	Animals dead after neurol. changes	Time of autopsy days post-irrad.
12	1 336	10	4	7	9—10	1	2	—	13 or 23
12	1 581	4	9	4	15	—	—	—	23
12	1 308	8	14	4	22—31	—	4	2	34
6	892	8	5	7	11—12	1	—	2	22
6	683	8	11	4	23—24	3	1	—	39 or 70
6	635	8	14—15	1	47	7	—	—	63
3	1 363	8	4—5	8	10—12	—	—	1	18
3	1 023	8	11	—	—	8	—	—	63
3	933	8	14	(1)	—	8	—	—	70
1.5	2 602	8	4—5	—	—	8	—	—	69 or 70
1.5	1 456	8	9	—	—	8	—	—	70
1.5	3 418	8	14—15	—	—	8	—	—	69 or 70
0.75	1 661	12	4—5	—	—	12	—	—	69 or 70
0.75	405	12	9—11	—	—	12	—	—	70
0.75	985	12	14—15	—	—	12	—	—	69 or 70

*Material and Methods.* Adult albino rats (Sprague-Dawley) were mated and the progeny were used in this experiment. The litter size was reduced to 6 soon after birth, with each litter containing both males and females, irradiated and control. During the irradiation procedure each rat was anesthetized (43 mg/kg nembutal, intraperitoneally) and placed on its back in a lucite box constructed with an aperture in the sides of the box at the site where the proton beam passed through the spinal cord.

The 185 MeV proton beam from the synchrocyclotron at the Gustaf Werner Institute, University of Uppsala was used in this investigation. Detailed information about the physical characteristics of this beam has been published previously (LARSSON et coll. 1959, LARSSON 1961). The beam measuring 5 mm cephalocaudally by 3 mm dorsoventrally was directed through the spinal cord. The position of the animal relative to the beam was ascertained by examination of roentgenograms superimposed on an autoradiogram of the beam. In order to determine whether or not the rat had moved during the irradiation procedure, roentgenograms were also obtained after irradiation; in no case did movement occur.

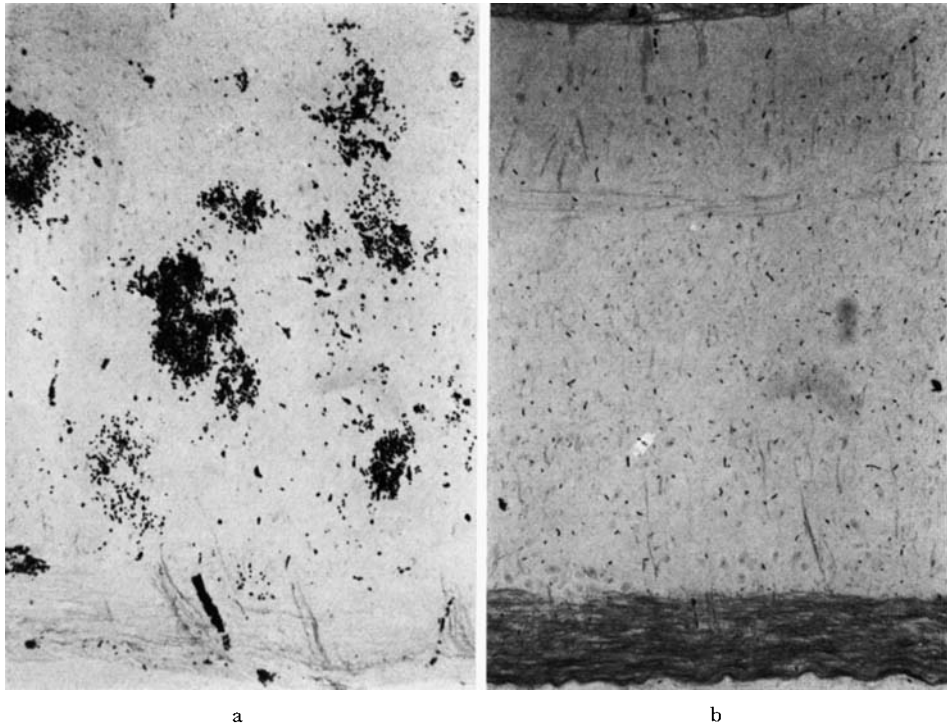


Fig. 2. a) Myelin preparation of irradiated region of spinal cord from rat receiving 12 krad when 4 days old and killed 13 days later. Very little stainable myelin in white matter; the blackened areas scattered throughout the section are hemorrhages. b) Normally staining myelin above the lesion shown in (a). The non-irradiated white matter is well-myelinated at this age (17) days. Mahon stain.  $\times 90$ .

The litters were divided into the following age groups: 3 to 5 days, 9 to 11 days and 14 to 16 days of age. A single dose of radiation at each of 5 levels (0.75, 1.5, 3.0, 6.0 and 12.0 krad) was given to litters of animals in each age group. The dose-rate varied within the range of 0.4 to 3.5 krad/min (cf. Table); the number of rats in each group at each dose level is shown in the Table. Following irradiation the animals were examined for neurologic changes for periods up to 70 days post-irradiation; the length of the observation period was dependent upon the general condition of the animal, and those appearing to be moribund were killed immediately.

All animals were killed by decapitation. A portion of the vertebral column containing both irradiated and adjacent non-irradiated areas of spinal cord was rapidly excised. After laminectomy the tissues were immersed in 10 % neutral formal-saline for at least three days, after which the spinal cords were dissected

from the remaining portions of the vertebrae. The spinal cords were embedded in paraffin, and serial longitudinal sections were cut at 10  $\mu$ , and stained according to the following procedures: gallocyanin, hematoxylin and van Gieson, hematoxylin and eosin, cresyl echt violet Mahon's method for myelin, and Palmgren's method for axis cylinders.

### Results

The data presented below are summarized in the Table. The most common neurologic abnormality was bilateral flaccid paralysis of the hindlimbs, and, since this and other types of neurologic deficits in the hindlimbs have been described in detail in two previous publications (GILMORE 1963a, 1964), they will not be repeated here.

*12 krad.* Seven of the ten animals irradiated at 4 days of age had neurologic abnormalities that were first noted at 9 to 10 days following irradiation. Two rats died before the appearance of any neurologic alterations, i. e. before 9 to 10 days following irradiation, and one remained normal throughout the experimental period. None of the animals with impairment of the hindlimb function had incontinence of urine.

Two of the rats were autopsied at 13 days post-irradiation, and the remaining six on the 23rd day following irradiation. Microscopic examination of spinal cords from animals killed at 13 days following irradiation revealed an obvious decrease in the number of neuroglia throughout the irradiated area (cf. Fig. 1). This same area was almost devoid of myelin (Fig. 2a), whereas non-irradiated areas were well-myelinated (Fig. 2b). Neurons were abundant in the irradiated region and only a few were undergoing chromatolysis. Hemorrhages were noted in both the gray and white matter (Fig. 2a) and vessels in the zone between irradiated and non-irradiated areas were dilated and congested. The histologic changes seemed to progress from those just described to necrotic foci filled with gutter cells and debris in the spinal cords of those animals that were killed 23 days following irradiation (Fig. 3). In addition to the vascular changes described above, polymorphonuclear leucocytes were abundant in the vessels. Irradiated areas that were not necrotic had fewer neuroglia than did normal, non-irradiated areas. The neurons, of course, were destroyed in the areas of necrosis, and some of those remaining in the adjacent areas were undergoing chromatolysis. Myelin alterations were similar in distribution to those already described, and axis cylinders were destroyed in necrotic areas. In addition to the changes noted microscopically, gross examination showed that the diameter of the irradiated areas was less than that of the non-irradiated portions.

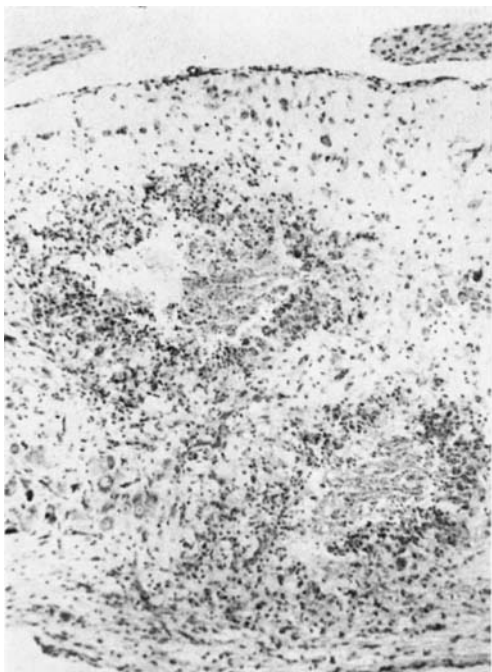


Fig. 3. Longitudinal section through lumbar spinal cord of rat irradiated with 12 krad when 4 days old and killed 23 days later. Two large cystic areas containing debris and gitter cells and surrounded by reactive cells; these two adjacent necrotic areas almost transect the spinal cord. Cresyl echt violet stain.  $\times 90$ .




Fig. 4. Lumbar region of spinal cord 23 days following administration of 12 krad to this structure in a 9-day-old rat. The ventral white matter is completely necrotic and the necrotic area extends for a short distance into the gray matter; throughout the section there is an increase in the number of cells. Hematoxylin-van Gieson stain.  $\times 90$ .

All animals irradiated when 9 days old developed changes in the neurologic status of the hindlimbs at 15 days following irradiation. Severe, concurrent alterations in bladder function made it impossible to extend the observation period beyond 23 days post-irradiation. The spinal cords from these animals were necrotic, with the greater extent of the necrosis in the white matter (Fig. 4). Large cavities in the latter interrupted the continuity of axis cylinders (Fig. 4) and only fragments of myelin were stained in such areas, whereas non-irradiated regions appeared to be well-myelinated. Gitter cells were abundant in necrotic foci. Neuronal degeneration was widespread, but the cavities in the gray matter were not as numerous nor as large as were those in the white matter. Hemorrhages were noted in both the gray and white matter, and vascular dilatation and congestion were evident throughout the irradiated region and at the junction between this and the non-irradiated areas. Endothe-

lial cells were obviously swollen and their nuclei formed prominent bulges into the vascular lumina. The number of cells in non-necrotic, irradiated regions was increased due to a proliferation of glial cells. Nuclei of astrocytes were enlarged and irregularly shaped, and contained discrete, darkly stained basophilic rods.

Four of the 8 rats irradiated when 14 days old died within two weeks following irradiation; none had developed neurologic alterations during that period. The other four animals developed neurologic abnormalities which became evident in one rat at 22 days post-irradiation and in the other three at 29 to 31 days following irradiation. Two of these rats died several days after the onset of neurologic changes and the remaining animals had to be killed at 34 days following irradiation because of their moribund condition.

The microscopic changes in spinal cords from these animals were essentially the same as those already described for animals irradiated when 9 days old. One alteration already described, but much more pronounced in these animals, was hypertrophy and hyperplasia of neuroglia; aggregations of microglia or microglial stars were frequently seen in the gray matter.

*6 krad.* Seven of the eight rats irradiated when 5 days old had neurologic changes at 11 to 12 days following irradiation; two of the seven died subsequent to the onset of these changes. The eighth animal died 17 days after irradiation but had remained normal neurologically during this period. Incontinence of urine was noted in some at the same time as the functional deficits of the hindlimbs were noted, but in others this visceral abnormality was not evident until as late as 9 days after onset of somatic changes. The surviving rats were killed 22 days following irradiation. The histologic appearances of the spinal cords were essentially the same as noted in the previous groups receiving 12 krad at a comparable age and can be summarized as follows: necrosis in center of irradiated area, cavities filled with gitter cells and debris primarily in white matter, destruction of axis cylinders, almost complete loss of myelin from the lesion with apparently well-myelinated white matter above and below, chromatolysis, large irregularly-shaped astrocytes, decrease in number of neuroglia in non-necrotic portions of irradiated area, hemorrhages and vascular dilatation in both gray and white matter, and vascular dilatation in the transitional zone between irradiated and non-irradiated areas.

Irradiation of eight rats 11 days old resulted in the development of neurologic abnormalities in 4 of these 23 to 24 days later. One animal died immediately after irradiation and three remained normal throughout the experimental period. The four rats with neurologic changes developed incontinence of urine within a week following the onset of disturbances in the hindlimbs and

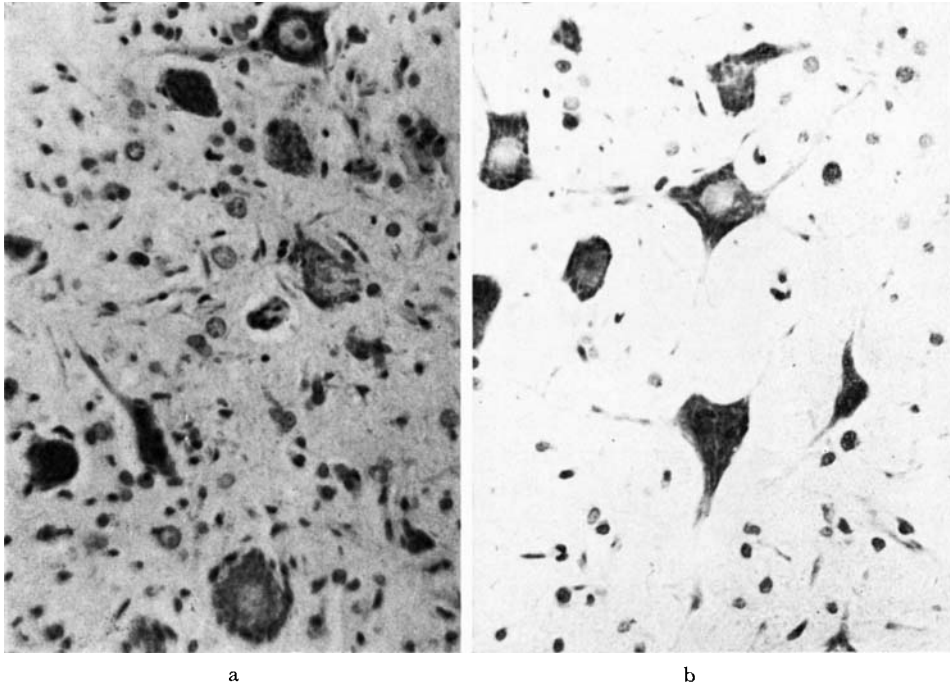


Fig. 5. a) High-power view of gray matter in spinal cord of rat irradiated with 6 krad at 14 days of age and killed 63 days later. The number of neuroglia is much greater than is seen in the control section (b); there is enlargement of some neuroglia and increase in the number of 'satellite' cells of the neurons. b) High-power view of gray matter from normal rat of the same age (77 days) as shown in (a). Cresyl echt violet stain.  $\times 650$ .

had to be killed 39 days following irradiation. The histologic changes within the spinal cords of these animals will not be repeated here because they are the same as those described for the comparable age group receiving 12 krad. The rats that did not show any neurologic abnormalities were killed on day 70 following irradiation and no histologic changes were seen in their spinal cords.

Only one of the eight animals irradiated when 14 to 15 days of age had neurologic changes which became evident at 47 days after irradiation. The other animals remained normal neurologically during the experimental period and all were killed 63 days following irradiation. The microscopic alterations already described in previous groups were also seen in the spinal cord of the one rat with neurologic abnormalities of the hindlimbs. In the other animals, however, histologic changes were seen in spite of the fact the rats appeared to be normal neurologically. The mildest change was an increase in number of cells in the irradiated regions of the spinal cords (cf. Fig. 5); this increase was

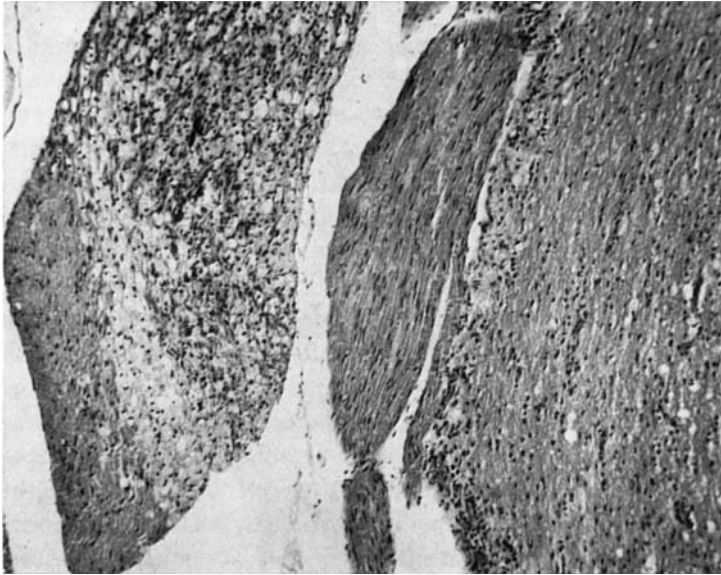


Fig. 6. Section showing nerve roots from rat irradiated with 6 krad when 14 days old and killed 63 days later. A portion of this root appears to be unstained and vacuolated and is highly cellular due to the presence of numerous phagocytic cells. Hematoxylin and eosin stain.  $\times 100$ .

noted particularly in the gray matter and was due to neuroglial proliferation. In the same area the astrocytic nuclei were hypertrophied and the nuclear membranes were quite prominent. Endothelial cells were hypertrophied and the vessels were slightly dilated. Some of the large motor neurons of the ventral horn region had an increased number of 'satellite' cells (Fig. 5a); whether these cells were microglia or oligodendroglia is not certain at this time. There was no evidence of necrosis within the spinal cords, but small areas of degeneration were found in the spinal roots (Fig. 6). Other spinal cords from neurologically normal rats had changes similar to but of greater severity than those just described. The most severe changes were seen in only one spinal cord in which cavities were beginning to form in the white matter. Degeneration of myelin and presence of phagocytic cells were noted in the spinal roots of this animal also. This is the first group within which such variations in the type and the extent of the pathologic changes were noted at the same post-irradiation interval and in which histologic changes existed in the absence of neurologic abnormalities.

*3 krad.* All rats irradiated when 4 or 5 days old developed neurologic abnormalities 10 to 12 days later. One died soon after the onset of these abnormali-

ties and the others were killed 18 days post-irradiation. The same severe histologic alterations described in spinal cords of animals irradiated at a comparable age and killed 23 and 22 days following irradiation with 12 and 6 krad, respectively, were seen in these animals.

All rats receiving 3 krad when 11 days of age remained normal neurologically throughout the 63-day experimental period. No histologic changes were noted within the spinal cords of these animals, but a small area of degeneration had developed in a spinal nerve root of one rat.

A transient period of slight neurologic difficulty occurred in one of the eight rats irradiated when 14 days old; this change, consisting of an inability to use the ankles properly, was noted at 39 days following irradiation and persisted for about one week, after which the animal appeared to be normal. The remaining seven animals appeared to be normal throughout the experiment. All rats were killed at 70 days following irradiation. The spinal cords were normal histologically with the exception of one which had slight changes consisting of swollen endothelium and proliferation of oligodendroglia and astroglia with nuclear hypertrophy in the latter. There were no other changes in neurons, myelin, axis cylinders or vascular system. Spinal roots from several spinal cords, however, did have small areas of degeneration.

*1.5 krad and 0.75 krad.* Regardless of age at the time of irradiation, all animals receiving 1.5 krad and 0.75 krad remained normal throughout the observation period. All rats in these groups were killed 69 or 70 days following irradiation and no microscopic changes were noted in any of the spinal cords.

### Discussion

The data presented above indicate that the incidence of neurologic abnormalities resulting from irradiation of the neonatal nervous system is related to both age at the time of irradiation and to the amount of radiation administered.

The effectiveness of 12 krad in inducing changes is evidenced by the occurrence of neurologic abnormalities in 50 % or more of the animals in all age groups. When the total dose of radiation is decreased to 6 krad there is still a high incidence of neurologic changes in the two younger groups but a decreased incidence in the oldest group. These data pertaining to the 6 krad group are different from those obtained in a previous study (GILMORE 1964) in which it was noted that the same amount of high energy protons produced a high incidence of neurologic abnormalities regardless of age at time of irradiation. A comparison of experimental methods and conditions shows one difference to be in the dose rate. In the earlier experiment the dose rate was 1 250 to

1 700 rad/min, whereas the same amount was delivered at 635 to 892 rad/min in this experiment. Data pertaining to the relationship between dose rate and radiation-induced changes in the central nervous system are sparse (HICKS 1956, ZEMAN 1961) so that the influence, if any, of this factor on the results presented by this investigation cannot be surmised. With a further decrease of the quantity of radiation to 3 krad it was found that this dose was effective in producing neurologic abnormalities in the youngest group only. Whether or not neurological alterations would have occurred after the observation period of 63 or 70 days cannot be stated and it is unfortunate that circumstances did not permit this observation period to be extended several more months. The smallest doses of radiation in this experiment, i. e. 1.5 and 0.75 krad, did not produce any neurologic changes in any of the animals regardless of age at the time of irradiation. It could be concluded then that within the conditions and time limitations of this experiment the smallest amount of radiation which produced neurologic abnormalities in any age group was between 1.5 krad and 3.0 krad, and that the smallest amount effective in producing some degree of neurologic disturbance in all age groups was between 3.0 krad and 6.0 krad.

One aspect of the neurologic studies that deserves comment is the latent period, i. e. the time between irradiation and the onset of observable neurologic abnormalities. Among the older groups receiving 12 krad and 6.0 krad the length of the latent period was found to be related directly to the age at the time of irradiation, and inversely to the amount of radiation administered. In contrast, the rats in the youngest group manifested these abnormalities at 9 to 12 days after irradiation regardless of the amount of radiation administered (3 krad to 12 krad). Since this latent period was so constant and short, and since the youngest animals receiving 1.5 krad were still apparently normal as late as 69 and 70 days after irradiation, these data would indicate that 1.5 krad is incapable of producing neurological abnormalities, or that if such abnormalities did occur at a much later time they would probably be etiologically different from those seen at 9 to 12 days following irradiation. The constancy of the 9 to 12 day latent period was also noted in this investigator's earlier works (GILMORE 1963a, 1964).

The pattern of the incidence of neurologic abnormalities and of the latent periods in relation to age and amount of irradiation is similar to that reported by YAMAZAKI et coll. (1960) following roentgen irradiation of the heads of rats 8 hours to 25 days of age. These investigators found that the greatest incidence of neurologic abnormalities occurred in animals irradiated during the first few days postnatally and that the incidence of these changes increased with the amount of radiation administered. The exception to this in the present study is

that almost all of the youngest rats receiving 3 krad to 12 krad developed neurologic changes and that the difference in amounts of radiation did not alter this incidence. YAMAZAKI et coll. (1960) also noted that the latent period increased with increasing age and decreasing dose. In the present investigation the exception to this pattern is the youngest group for which the latent was 9 to 12 days regardless of the amount of radiation administered.

The studies of the microscopic changes found histologically in the spinal cords from most rats receiving 12 krad, and from the 3 to 5 day and 9 to 11 day groups receiving 6 krad, indicated that these amounts of radiation can produce very severe damage in the central nervous system. The data also indicated that these changes developed very rapidly since the studies were made on spinal cords from animals that had been killed at about 5 weeks or less following irradiation. Whether or not the remaining rats receiving 6 krad at 9 to 11 and 14 to 15 days of age would have developed severe histologic changes with subsequent neurologic abnormalities is still open to question. In some of these it was interesting to note that there was an increased number of neuroglia throughout the irradiated areas or, in some cases, an increase in satellite cells. In addition, cavities were beginning to form in the white matter and degenerative changes in the spinal roots were seen in one animal. On the basis of these histologic changes one might hypothesize that neurologic abnormalities could have developed in a few more rats if the length of the experimental period had been extended.

In contrast to the higher doses of radiation, 3 krad was effective in producing severe pathologic changes in only the youngest group. Only one spinal cord from rats given this amount when 9 to 11 or 14 to 16 days of age had histologic alterations and this was from the rat that had had a period of transient paralysis. All other spinal cords were normal with the exception of several in which small areas of degeneration were beginning to form in the spinal nerve roots. Since some pathologic changes were becoming evident in the spinal roots one might hypothesize again that an extension of the experimental period would have given different results in terms of incidence of neurologic abnormalities and of latent periods.

The long-term effects of 1.5 krad and 0.75 krad would be of interest in view of the changes that are known to occur in the central nervous system of adult rats at considerably long intervals following irradiation (ZEMAN 1961, INNES & CARSTEN 1961a, 1961b). In addition, a study of neurologic abnormalities and histologic changes resulting from amounts of radiation between 1.5 krad and 3 krad would be of interest in determining why such different results occur when these amounts of radiation are administered to 3 to 5 day old rats.

This study has shown that within the dose, age and time limits of this

experiment the neurologic and neuropathologic observations are related to the age at the time of irradiation and to the quantity of radiation administered. In addition to these observations the data have indicated that the dose rate is a factor to be considered in biologic experiments, but it is not likely that the dose-rate variation recorded during this experiment would alter the basic conclusions drawn in this paper. The data obtained from the groups receiving the smallest doses of radiation also stress the need for long-term studies in this area. Further investigation of these aspects as well as of the varying degrees of oxygenation in the individual animals, and perhaps also of the varying states of development in animals of the same extrauterine age, are needed for a more complete understanding of the response of the immature nervous system to ionizing radiation.

### Acknowledgements

Sincere appreciation is extended to Professor Bror Rexed and to Docent Börje Larsson whose aid, advice and efforts made this experiment possible, to the cyclotron crew for their efforts in providing the proton beam, and to Miss K. Hagman for preparation of the histologic material. The financial support was through USPHS Postdoctoral Research Fellowship BF-10, 691-C2 and the USAF School of Aerospace Medicine under Contract AF 61(052)-740 through the European Office of Aerospace Research (OAR) United States Air Force.

### SUMMARY

Single doses of high-energy protons ranging from 0.75 krad to 12 krad were administered to limited portions of spinal cords of neonatal rats when 3 to 5, 9 to 11, or 14 to 16 days of age. The incidence of neurologic abnormalities in the hindlimbs and the time between irradiation and onset of these abnormalities were studied and are discussed with respect to age when irradiated and amount of radiation. The microscopically pathologic changes of the spinal cords are reported and discussed in relation to age, dose and the neurologic status of the animal.

### ZUSAMMENFASSUNG

Einzel Dosen von hochenergetischen Protonen von 0.75 bis 12 krad wurden umschriebenen Gebieten des Rückenmarks neugeborener Ratten im Alter von 3 bis 5, 9 bis 11, 14 bis 16 Tagen verabreicht. Das Auftreten von neurologischen Veränderungen der hinteren Extremitäten sowie das Zeitintervall zwischen Bestrahlung und dem Auftreten dieser Schädigungen wurde studiert und mit Hinsicht auf das Alter und die Strahlendosis diskutiert. Es werden die mikroskopischen Befunde des Rückenmarks mitgeteilt und mit Hinsicht auf Alter, Dosierung und den neurologischen Status des Versuchstieres besprochen.

## RÉSUMÉ

Des doses uniques de protons de haute énergie, comprises entre 0.75 krad et 12 krad ont été administrées à des portions limitées de la moelle épinière de rats nouveau-nés âgés de 3 à 5, 9 à 11, ou 14 à 16 jours. L'auteur a étudié la fréquence et le délai d'apparition de troubles neurologiques des membres postérieurs en fonction de l'âge au moment de l'irradiation et de la quantité de rayonnement. Il décrit les lésions histologiques de la moelle épinière et les étudie en fonction de l'âge, de la dose et des signes neurologiques.

## REFERENCES

- CLEMENTE C. D., YAMAZAKI J. N., BENNETT L. R. and McFALL R. A.: Brain radiation in newborn rats and differential effects of increased age. II. Microscopic observations. *Neurology* 10 (1960), 669.
- FÖRSTERLING K.: Über allgemeine und partielle Wachstumstörungen nach kurzdauernden Röntgenbestrahlungen von Säugethieren. *Arch. klin. Chir.* 81 (1906), 505.
- GILMORE S. A.: (a) The effects of x-irradiation on the spinal cords of neonatal rats. I. Neurological observations. *J. Neurophath. exp. Neurol.* 22 (1963), 285.
- (b) The effects of x-irradiation on the spinal cords of neonatal rats. II. Histological observations. *J. Neuropath. exp. Neurol.* 22 (1963), 294.
- Responses of neonatal rat spinal cords to high energy protons. *Acta radiol.* 2 (1964), 81.
- HICKS S. P., WRIGHT K. A. and LEIGH K. E.: Time-intensity factors in radiation response. I. The acute effects of megavolt electrons (cathode rays) and high- and low-energy x-rays with special reference to the brain. *Arch. Path.* 61 (1956), 226.
- INNES J. R. M. and CARSTEN A.: (a) Delayed effects of localized x-irradiation of the nervous system of experimental rats and monkeys. *Brookhaven Symposia in Biology* 14 (1961), 200.
- (b) Demyelinating or malacic myelopathy. A delayed effect of localized x-irradiation in experimental rats. *Arch. Neurol.* 4 (1961), 190.
- LARSSON B.: Pre-therapeutic physical experiments with high-energy protons. *Brit. J. Radiol.* 34 (1961), 143.
- LEKSELL L., REXED B. and SOURANDER P.: Effects of high-energy protons on the spinal cord. *Acta radiol.* 51 (1959), 52.
- SCHOLTZ W.: Über den Einfluss der Röntgenstrahlen auf die Haut in gesundem und krankem Zustande. *Arch. Dermat. Syph (Berl.)* 59 (1902), 87.
- YAMAZAKI J. N., BENNETT L. R., McFALL R. A. and CLEMENTE C. D.: Brain radiation in newborn rats and differential effects of increased age. I. Clinical observations. *Neurology* 10 (1960), 530.
- ZEMAN W.: Radiosensitivities of nervous tissues. *Brookhaven Symposia in Biology* 14 (1961), 176.