

RADIOLOGIC TREATMENT OF ORBITAL LYMPHOMA

by

SUNE AHLSTRÖM, MARTIN LINDGREN and HANS OLIVECRONA

Lymphomas represent a comparatively small group of orbital tumours. GODTFREDSSEN (1947), OFFRET (1951) and REESE (1951) found about 15 per cent of lymphomas in their respective materials of growths of the orbit. GODTFREDSSEN & LINDGREN (1953) published an account of a series of 12 orbital lymphomas. Apart from LEDERMAN (1956, 1957, a and b) who reported the technique and results of radiation treatment, most authors have studied these tumours chiefly from an ophthalmologic point of view. The increasing knowledge of the histology and clinical course of orbital lymphomas has resulted in a change of treatment from the earlier combined surgical-radiologic treatment to nowadays accepted radiotherapy alone.

Material. Nine patients with orbital lymphoma, three of whom had bilateral growths were treated during the period 1946—1959. The tumours comprised seven orbital, three epibulbar, one palpebral, and one intraocular growths; they all had smooth surfaces and were of a soft, elastic consistency. The anterior part was well outlined, but for anatomical reasons the position of the posterior part could not be determined exactly, which is important from a radiotherapeutic standpoint.

Submitted for publication 23 December 1964.

The tumours were examined histologically in all nine instances. Biopsy was performed on one side only in the 3 patients with a bilateral growth; a malignant lymphoma was revealed in 3 patients, but in the remaining 6 patients the appearances were difficult to interpret. The growth was composed of densely packed lymphocytes, and the formation of follicle-like structures was observed occasionally (Fig. 1). BÄFVERSTEDT, LUNDMARK, MOSSBERG & STENBECK (1956) have reported one instance of lymphoma of the orbit with similar histologic appearances, and suggested that they were identical with those of lymphadenoma benigna cutis, described by BÄFVERSTEDT (1943).

Case reports

Case 1. Female, aged 66, who had had a tumour in the upper medial aspect of the left orbit for six months. Biopsy revealed malignant lymphoma.

July 1957. Roentgen therapy in one series against an upper anterior and a lateral orbital field with a dose to each of 1 500 rad over a period of 11 days produced complete regression of the tumour by the end of the treatment.

November 1957. Enlarged lymph nodes noted in both groins and axillae, and small tumours in the skin of the left breast; biopsy of the latter revealed malignant lymphoma. Roentgen therapy resulted in the disappearance of the changes.

February and July 1963. The examination of small tumours extirpated from the right thigh disclosed malignant lymphoma.

May 1964. Patient well and free of symptoms.

Case 2. Male, aged 61, who had had a tumour in the upper medial aspect of the right orbit for nine months proved on biopsy to be a malignant lymphoma.

August 1957. Roentgen therapy in one series against an upper anterior orbital field with a dose of 2 800 rad over a period of 8 days resulted in complete disappearance of the tumour; no growth present one month later. Free of symptoms until December 1962 when a mass appeared in the left gluteal region.

May 1963. Enlarged lymph nodes noted in the right inguinal region. Biopsy from both locations disclosed malignant lymphoma. Cavography demonstrated a right-sided pelvic tumour. Roentgen therapy against both sides of the pelvis.

May 1964. Enlarged lymph nodes appeared on the right side of the neck. Biopsy revealed malignant lymphoma of the same appearances as at earlier investigations. Roentgen therapy administered.

September 1964. Patient well and free of symptoms.

The patient died in November 1964; autopsy revealed malignant lymphoma in abdominal lymph nodes and in the liver.

Case 3. Female, aged 51, who had had a slowly growing tumour at the medial aspect of the base of the left orbit for sixteen months.

September 1946. The tumour was partially removed and was considered to be either a lymphosarcoma or a benign lymphadenoma. Roentgen therapy was given in two series against an anterior orbital field with a dose of 2 800 rad over a period of 56 days; the first series also

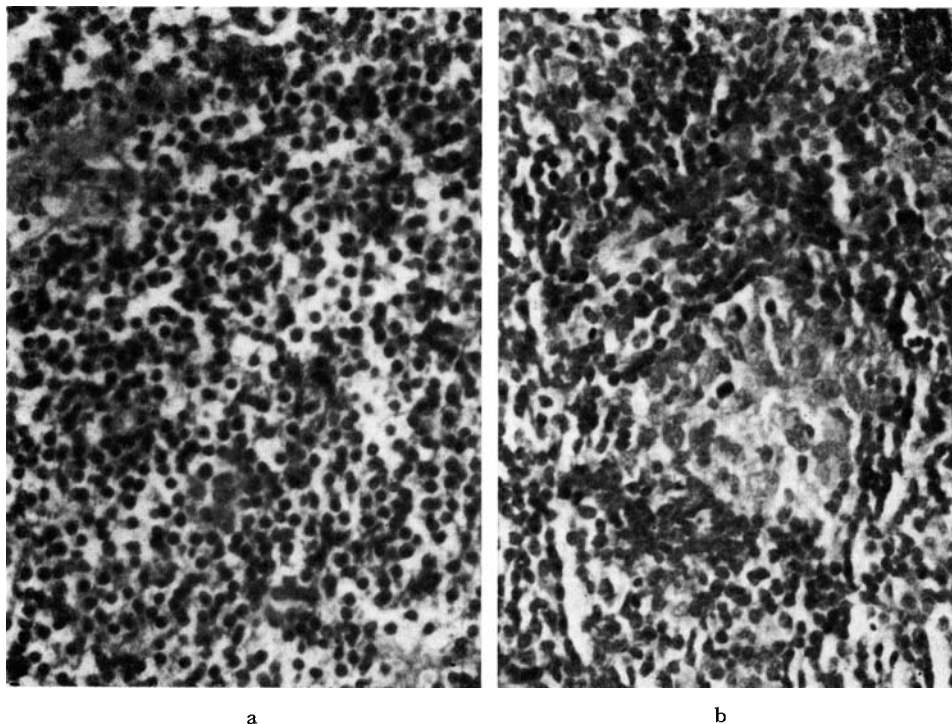


Fig. 1. Microscopic appearance of an orbital lymphoma. a) Evenly distributed, densely packed lymphocyte-like cells. b) Development of a follicle-like structure. $\times 400$.

included a lateral orbital field with a dose of 1 500 rad over a period of 9 days. The treatment resulted in successive decrease of the growth and ultimately its complete disappearance.

October 1949. A small tumour of the right breast was removed and proved to have similar microscopic appearances as the lesion in the orbit; interpreted as probably being a benign lymphadenoma.

November 1964. Patient well and free of symptoms.

Case 4. Male, aged 65, who had had a slowly growing tumour located subconjunctivally and medially in the right eye for eighteen months.

June 1948. Biopsy showed the tumour to be probably a benign lymphadenoma. Roentgen therapy administered against an anterior orbital field with a dose of 1 000 rad over a period of 5 days. One month later a small rest of tumour persisted; contact roentgen therapy, given on one occasion in a dose of 1 000 rad (50 kV, 2 mm Al, HVD 8 mm H₂O), caused its complete disappearance within three months.

November 1954. A tumour present in the left mammary appeared on microscopy to be a benign lymphadenoma; it was treated with roentgen therapy.

November 1955. A tumour was observed in the subconjunctiva of the left orbit; no biopsy was performed. Roentgen therapy in one series against an anterior orbital field with a dose of 1 300 rad over a period of 9 days caused complete regression of the tumour within a month.

February 1957. The patient was operated on for carcinoma of the stomach. In addition to an adenocarcinoma, microscopy revealed a malignant lymphoma located in the gastric mucosa and in abdominal lymph nodes.

The patient died in August 1959.

Case 5. Male, aged 82, who on two occasions during the previous three years had had a temporary protrusion of the right eye, a condition that had become permanent during the previous twelve months. A tumour evident in the upper part of the right orbit appeared on biopsy to be a benign lymphadenoma. Roentgen therapy against an upper anterior and a lateral orbital field with a dose to each field of 1 500 rad over a period of 10 days produced disappearance of the tumour two months later.

October 1958. A growth that now was present at the lower margin of the right orbit had the same appearances on microscopy as the previous tumour. Roentgen therapy was given against an inferior anterior orbital field with a second series against the same lateral field as treated earlier; each field received a dose of 1 500 rad over a period of 12 days. No growth was evident two months later.

February 1959. A tumour, of appearance similar to the previous growths, appeared in the right parotid region and was again treated with roentgen therapy.

April 1963. Patient well and free of symptoms.

The patient died in October 1964 from cardiosclerosis.

Case 6. Female, aged 47, with slowly increasing left exophthalmus for six months.

February 1950. Biopsy of a left orbital tumour suggested a benign lymphadenoma. A small growth was also present in the right upper eyelid. Roentgen therapy in two series was given against both orbits. On the left side, two lateral fields, a lower at the level of the orbit and an upper field over the lateral frontal region were used; treatment on the right side was given against an anterior and a lateral orbital field. The dose in the two series to each field on the left side was 2 400 rad over a period of 75 days and on the right side, 2 100 rad over a period of 63 days. A rapid decrease of the tumour mass occurred on both sides, and within five months the tumours had disappeared.

November 1964. Patient well and free of symptoms.

Case 7. Female, aged 46, with downward displacement of the right eye for a month.

May 1947. A growth in the upper part of the right orbit which on biopsy appeared to be a benign lymphadenoma. Roentgen therapy in two series against an upper anterior orbital field with a dose of 3 500 rad over a period of 53 days resulted in disappearance of the tumour two months later. Free of symptoms until December 1957 when bilateral inguinal lymph nodes enlargement was proved to be due to malignant lymphoma. The disease rapidly progressed with several new manifestations and the patient died in July 1958.

Case 8. Female, aged 55, who had had a tumour of the soft palate for five months.

November 1949. Biopsy suggested the presence of a malignant lymphoma. Roentgen therapy resulted in complete disappearance of the signs.

October 1954. A tumour that had appeared subconjunctivally on the upper medial aspect of the right eye, was found on microscopy to have appearances similar to those of the soft palate. Roentgen therapy in two series against an anterior orbital field in a total dose of 2 000 rad over a period of 42 days caused the tumour to disappear.

September 1959. Impaired vision of the left eye was found to be due to an intraocular tumour that had caused ablatio retinae; a retrobulbar tumour had produced protrusion of the eye.

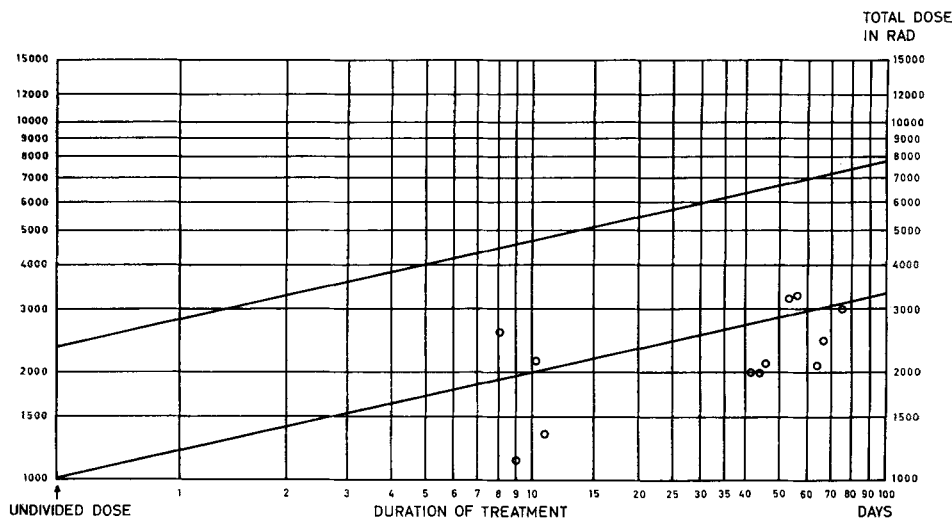


Fig. 2. Strandqvist-diagram showing the tumour dose given in 12 instances of orbital lymphoma. The upper line represents the dose needed for healing cancer of the skin; the lower line shows the dose levels on different days corresponding to a single dose of 1 000 rad.

Biopsy could not be performed. Roentgen therapy in two series against a lateral orbital field with a total dosage of 3 200 rad over a period of 45 days resulted in the disappearance of the tumour and the ablatio. Before treatment, the visual acuity was 0.1, and after treatment it rose temporarily to 0.3 but later fell to 0.1 because of an incipient irradiation cataract.

February 1961. A tumour extirpated from the left arm proved to be a malignant lymphoma. Roentgen therapy was given.

July 1961. Roentgen therapy was administered to a tumour of the right cheek; no biopsy.

February 1963. A small tumour in the right breast proved on biopsy to be a malignant lymphoma; it was treated with roentgen therapy.

October 1964. A tumour of the upper lip proved on biopsy to be a malignant lymphoma; roentgen therapy caused complete regression.

November 1964. Patient was in good general health.

Case 9. Male, aged 58, had had right exophthalmus for the previous six months. A tumour situated in the upper medial aspect of the orbit was considered on biopsy to be either a benign lymphadenoma or a lymphosarcoma. Roentgen therapy in two series: (1) against an upper and a lower orbital field, as well as against a lateral orbital field, (2) against only the lateral orbital field. The dose to the two anterior fields was 1 000 rad against each over a period of 11 days and the dose to the lateral field in the two series was 3 000 rad over a period of 56 days. Two months after the beginning of the treatment there was complete regression of the exophthalmus and no growth was evident in the orbit. Slight paresis of the superior oblique and the inferior rectus muscles was noted; later about a 2 mm degree of enophthalmus was observed.

October 1964. Patient well and free of symptoms.

Radiation technique and results of treatment. Six patients were treated with 170 kV, HVL 1 mm Cu, one with 150 kV, HVL 0.35 mm Cu, and 2 with 100 kV, HVL 0.15 mm Cu; FSD 40 or 50 cm. Irradiation was given against 12 tumour localizations in these 9 patients; in 10 of these 12, a single anterior field was given against the orbit, and in 5 was supplemented with a lateral field. The intraocular tumour, which caused ablatio retinae, was treated only against a lateral field. One patient with a growth situated laterally in the orbit received treatment against both a lateral orbital field and a field against the outer part of the forehead.

Lead protection of the cornea was employed when a field was directed against the eye. The treatment was given with daily skin doses that varied from 150 to 300 rad. The tumour dose for each patient was calculated and recorded in a diagram according to STRANDQVIST (1944); it corresponded to an accumulated dose of about 1 000 rad (Fig. 2).

All the neoplasms were highly radiosensitive and they completely regressed. Complete disappearance of the tumour and further healing of the detachment of the retina occurred in the patient with ablatio retinae. The visual acuity of the treated eye first rose from 0.1 to 0.3 but later fell to 0.1 because of an incipient irradiation cataract. This patient was the only one with damage to the lens, the only complication encountered in the present material.

Discussion

The clinical manifestations and the different locations of the tumours in the region of the eye in the present material agree fairly well with those previously reported (McGAVIC 1943, FORREST 1949, HEATH 1949, OFFRET 1951, REESE 1951, GODTFREDSSEN & LINDGREN 1953). Three patients had bilateral growths.

The diagnosis is based on the histology of the tumour and the course of the condition. It is often impossible to refer the neoplasm conclusively to a certain type within the lymphoma group. The degree of malignancy in many instances cannot be determined histologically and the clinical course provides an indication of any malignant transformation of the disease. A fairly strong tendency for the pathologic process to spread with the appearance of new localizations was evident in the present material; thus signs appeared later of metastatic growths in seven patients with a primary lesion in the orbit. It therefore seems that, even though the primary tumour in the orbit does not definitely present evidence of malignant changes on microscopy, the condition has a considerable tendency to degenerate into a malignant form with generalization.

The neoplasms belong to the lymphoma group and can be expected to show a high degree of radiosensitivity; because of this, and the tendency for distant

spread, radiotherapy is to be preferred to surgery. All the orbital tumours in the present material were highly radiosensitive and disappeared completely; no local recurrence was evident. If the situation of the tumour allows protection of the cornea and lens, no damage to the eye occurs.

Because of the possibility of a malignant spread, patients with orbital lymphomas, which histologically need show no malignant characteristics, should be continuously controlled in the same manner as those with malignant growths.

SUMMARY

Orbital lymphoma in 9 patients treated with roentgen irradiation is described. Most of the tumours presented atypical appearances and the disease followed a varying clinical course with a tendency to malignancy with distant spread. All the tumours were highly radiosensitive and disappeared completely after an accumulated tumour dose of about 1 000 rad.

ZUSAMMENFASSUNG

Neun Fälle von Lymphom der Orbita wurden mit Röntgentherapie behandelt. Die meisten Tumoren erwiesen sich als atypisch und zeigten einen wechselnden klinischen Verlauf mit Tendenz zur Malignität und Neigung zu entfernten Metastasen. Alle Tumoren waren höchst strahlenempfindlich und verschwanden vollständig nach einer Totaldosis von ungefähr 1 000 rad.

RÉSUMÉ

Présentation de 9 cas de lymphome orbitaire traités par roentgen thérapie. La plupart de ces tumeurs avaient des aspects atypiques et ont eu une évolution clinique variable, avec une tendance à la malignité et à la dissémination à distance. Toutes ces tumeurs ont été très radiosensibles et ont disparu complètement après une dose tumeur totale d'environ 1 000 rad.

REFERENCES

- BÄFVERSTEDT B.: Über Lymphadenosis benigna cutis. Eine klinische und pathologisch-anatomische Studie. *Acta dermat.-venerol.* (Stockh.) 24 (1943), Suppl. 11.
- LUNDMARK C., MOSSBERG H. and STENBECK A.: Lymphadenosis benigna orbitae. *Acta ophthal.* 34 (1956), 367.
- FORREST A. W.: Intraorbital tumors. *Arch. Ophthal.* 41 (1949), 198.
- GODTFREDSSEN E.: Studies on orbital tumours. I. Nature and incidence of orbital tumours over a period of 15 years (1932—1946) from the Eye Department of Karolinska Sjukhuset. *Acta ophthal.* 25 (1947), 279.
- and LINDGREN S.: Orbital, palpebral and epibulbar lymphomas. Studies on orbital tumours 4. *Acta ophthal.* 31 (1953), 29.
- HEATH P.: Ocular lymphomas. *Amer. J. Ophthal.* 32 (1949), 1213.

- LEDERMAN M.: Radiotherapy in the treatment of orbital tumours. *Brit. J. Ophthal.* 40 (1956), 592.
- (a) Radiotherapy of non-malignant diseases of the eye. *Brit. J. Ophthal.* 41 (1957), 1.
- (b) Technique of radiation treatment of orbital tumours. *Brit. J. Radiol.* 30 (1957), 469.
- MCGAVIC J. S.: Lymphomatoid diseases involving the eye and its adnexa. *Arch. Ophthal.* 30 (1943), 179.
- OFFRET G.: *Les tumeurs primitives de l'orbite, leur traitement.* Masson, Paris 1951.
- REESE A. B.: *Tumours of the eye.* Cassell, London 1951.
- STRANDQVIST M.: Studien über die kumulative Wirkung der Röntgenstrahlen bei Fraktionierung. *Acta radiol.* (1944) Suppl. 55.