

## GASTRIC ENDOCRINE CELL PROLIFERATION AND FUNDIC ARGYROPHIL CARCINOID TUMORS IN PATIENTS WITH THE ZOLLINGER-ELLISON SYNDROME

GUILLAUME CADIOT, THÉRÈSE LEHY and MICHEL MIGNON

---

**The Zollinger-Ellison syndrome (ZES) is characterized by hyperchlorhydria due to sustained hypergastrinemia of tumoral origin. In ZES, as in all pathological and experimental conditions associated with chronic hypergastrinemia, endocrine argyrophil cells, particularly enterochromaffin-like cells, proliferate in the fundic mucosa. In patients with ZES, fundic argyrophil carcinoids only develop in those patients who also have multiple endocrine neoplasia type 1. The authors review factors which might influence fundic argyrophil cell proliferation in the ZES. Clinical characteristics of the patients with fundic argyrophil carcinoid tumors as well as pathology and the putative mechanisms of development of these tumors are described.**

---

Experimental conditions of achlorhydria in rats and atrophic gastritis or the Zollinger-Ellison syndrome (ZES) in man are models for the study of the consequences of long-term hypergastrinemia on fundic endocrine cells, particularly on enterochromaffin-like (ECL) cells. The ZES differs from the other two conditions by a tumoral origin for the sustained hypergastrinemia resulting in hyperchlorhydria (1) and also from atrophic gastritis by a non-atrophic fundic mucosa resembling that of patients with duodenal ulcer or peptic esophagitis.

Fundic argyrophil cell hyperplasia in patients with ZES is known since 1974 (2). The first cases of fundic argyrophil carcinoid tumors in the ZES have been described more recently (3). Up to now, 19 cases of fundic carcinoid tumors have been reported, most of them in the last 5 years (4-8), probably due to the facts that since total

gastrectomy is nowadays abandoned because of efficient new antisecretory drugs (1) and since the survival has been improved, the stomach of the ZES patients is exposed longer to factors that might influence fundic argyrophil cell proliferation. Furthermore, the long-term effect of antisecretory drugs on these cells is not clearly determined.

Only a few works have concerned systematic study of fundic argyrophil-ECL cell proliferation abnormalities in ZES (5, 7, 9-13). The present paper reviews factors which may influence fundic argyrophil cell proliferation and carcinoid development in patients with this syndrome and refers partly to personal observations in 48 ZES patients from Bichat hospital. Among them, 17 had the syndrome associated with multiple endocrine neoplasia type 1 (MEN 1).

### Fundic argyrophil cell hyperplasia in ZES

Thirty (14) to 45% (15) of the fundic argyrophil cells are ECL cells in healthy humans and 65% in patients with ZES (16). D'Adda et al. (16), using electron microscopy, reported that in ZES, among fundic endocrine cells, only ECL cells proliferated. Most articles dealing with fundic endocrine cells used techniques which do not distinguish ECL cells from other argyrophil cells. We will therefore use the term 'argyrophil cells' instead of ECL cells.

---

Received 23 September 1992.

Accepted 30 September 1992.

From the Department of Hepato-Gastroenterology and INSERM U10, Bichat-Claude Bernard Hospital, Paris, France (all authors).  
Correspondence to: Dr Michel Mignon, Dept of Hepato-Gastroenterology, Bichat-Claude Bernard Hospital, 46 rue Henri-Huchard, F-75877 Paris Cedex 18, France.

Presented at the 3rd International Workshop on Neuroendocrine Tumors held in Lofoten, Norway, June 24-28, 1992.

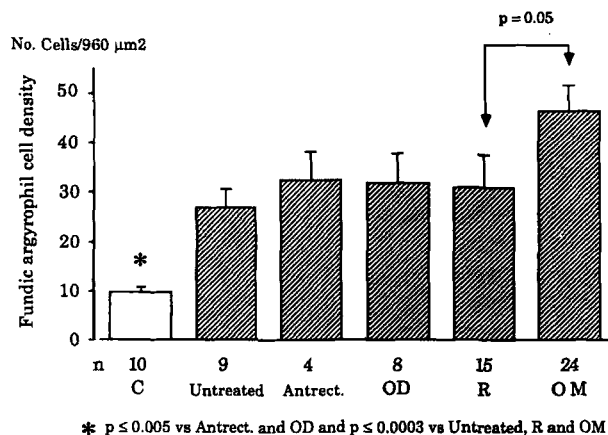


Fig. 1. Fundic argyrophil cell densities in controls (C) (from ref. 5) and in 48 patients with the ZES (personal data). Some patients with ZES have been studied during the course of different treatments. Untreated: ZES patients who never received antiseecretory drugs. Antrect: ZES patients with distal gastrectomy. OD: ZES patients treated with ranitidine + pirenzepine or octreotide ± ranitidine (median treatment duration: 48 months, range 3–63). R: ZES patients treated with ranitidine (median treatment duration: 48 months, range 12–113). OM: ZES patients treated with omeprazole (median treatment duration: 35 months, range 2–93).

Independently of the antiseecretory drugs received, 73–79% of the patients with ZES have fundic argyrophil cell hyperplasia (5, 10, 12). Recently, a panel of experts defined the different morphological degrees of hyperplasia (diffuse, linear, micronodular, adenomatoid), dysplasia and neoplasia (17). It has been shown that the volume density of fundic argyrophil cells was augmented by 168% in patients with ZES as compared to healthy subjects, using quantitative electron microscopy techniques (16). By quantitative light microscopy techniques, Maton et al. (10) showed that the percentage of fundic argyrophil cells in patients with ZES was twice that of patients with duodenal ulcer and normal serum gastrin levels. We found that the mean fundic argyrophil cell density was 3–4 times higher in patients with ZES than in controls with normal gastric acid and gastrin secretions (Fig. 1) (5, 7, 9).

#### Factors which might influence fundic argyrophil cell proliferation in ZES

##### Role of gastrin

Chronic hypergastrinemia is certainly the main factor responsible for argyrophil cell proliferation. As in atrophic gastritis (18) or in rats (19), we noted a positive significant correlation between fundic argyrophil cell density and serum gastrin level (Fig. 2a). Such a correlation has also been found in the subgroup of patients treated with omeprazole (personal data) (Fig. 2b). Maton et al. (10) did not notice any significant correlation between these two variables in 17 ZES patients treated with omeprazole. How-

ever, the correlation was significant after inclusion of their controls with normal serum gastrin. It should be pointed out that the range of serum gastrin in their patients was relatively narrow (10). Note that our gastrin RIA only measured G17 and G34 and not abnormal gastrin molecular forms which are sometimes secreted by gastrinomas (20) and may also act on argyrophil cell proliferation.

##### Role of antisecretory treatments

We compared the mean fundic argyrophil cell density in 5 groups of patients with ZES (personal data). It was of the same magnitude in patients who had never received any antisecretory drug at the time of the study, in those who had undergone partial distal gastrectomy, and in those who were treated with ranitidine (for 48 months, range 12–113) or 'other drugs' (ranitidine + pirenzepine, or octreotide alone or with ranitidine) (for 48 months, range 3–63) (Fig. 1). By contrast, the fundic argyrophil cell density was increased by 45 to 73%, as compared with other ZES groups, in patients who were treated with omeprazole for 35 months (range 2–93). From these data we cannot conclude that omeprazole treatment enhanced fundic argyrophil cell proliferation since, on many points the patients from the different groups were not comparable, namely number of patients, seriousness of the disease, evolution of the gastrinoma mass, and gastrin level.

The mean antral gastrin cell density was also determined in the same patients (personal data) (Fig. 3). It was quite similar in controls and in patients who had never received antisecretory drug. It was significantly higher in the ranitidine-treated patients than in controls ( $p < 0.05$ ) and in the omeprazole-treated patients than in all the other groups ( $p < 0.02$ – $p < 0.0001$ ), reflecting the constant nycthemera inhibition of acid secretion with this last drug. In patients treated with ranitidine, periods of iterative antral acidification occur between the drug administrations due to the shorter duration of acid reduction with that drug. Concerning antral gastrin cells, a similar phenomenon has been noted in rats by Ryberg et al. (21) who administered either omeprazole or ranitidine in doses intended to cause the same gastric acid secretory reduction. They noticed that it was not possible to obtain the same nycthemeral acid inhibition with ranitidine as with omeprazole, even with continuous infusion. Even if serum and antral gastrin levels and fundic argyrophil cell densities were not different between the 2 groups, an increase in antral gastrin cell density was only noted in the omeprazole-treated rats (21).

The long-term effect of omeprazole treatment on fundic argyrophil cell proliferation has been studied by Maton et al. (10), Hage et al. (13) and our group (9). Maton et al. (10) did not disclose any influence of omeprazole on the percentage of fundic argyrophil cells or on serum gastrin in 17 ZES patients treated for a median period of 28 months (maximum 3 years). Hage et al. (13) reported preliminary

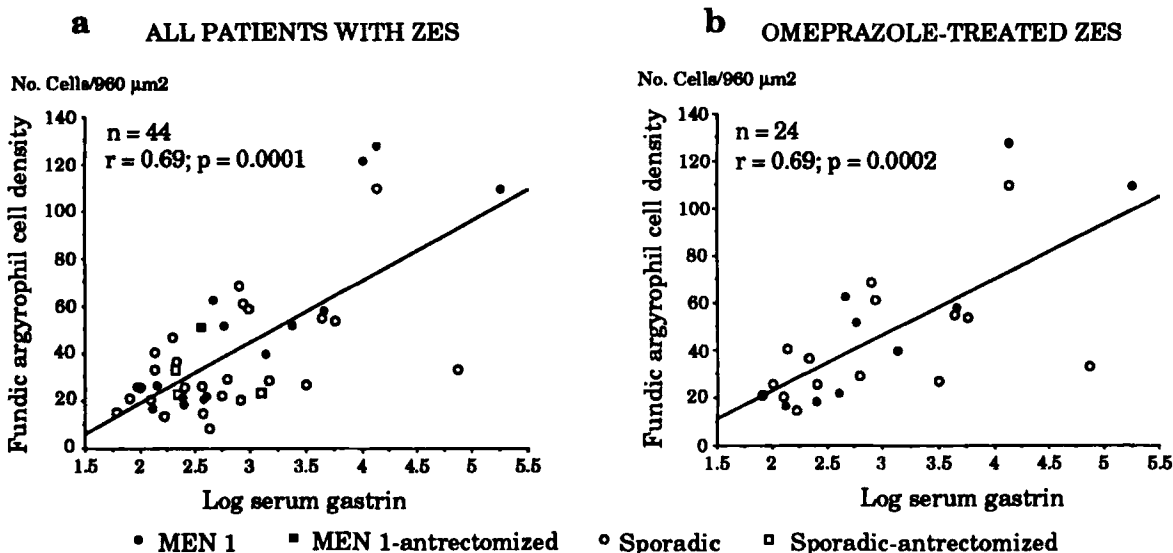


Fig. 2. Correlation between fundic argyrophil cell density and serum gastrin levels (expressed as log) in a) 44 patients with the ZES (same patient as in Fig. 1, 4 patients did not have serum gastrin determination) and b) 24 patients with the ZES treated with omeprazole for a median treatment duration of 35 months (range 2–93) (personal data). ● = MEN 1; ■ = MEN 1-antrectomized; ○ = sporadic; □ = sporadic-antrectomized.

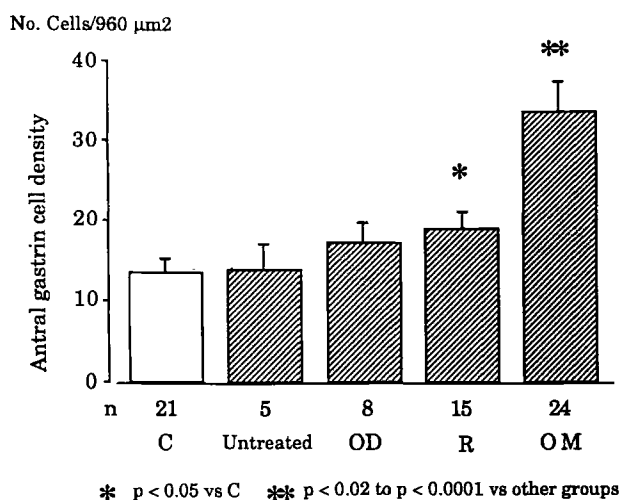


Fig. 3. Antral gastrin cell density in controls (C) (from ref. 5) and in patients with the ZES (personal data). For further explanation, see legend to Fig. 1.

results in 17 ZES patients treated with omeprazole for a longer time (median 51 months, up to 7 years). They showed that the degree of argyrophil cell hyperplasia slightly increased with time with a concomitant increase in serum gastrin (13). A fundic argyrophil carcinoid developed in one patient with MEN 1 after 7 years of treatment (13). We recently showed that fundic argyrophil cell density, antral gastrin cell density and the serum gastrin level significantly increased during a 36-month period of survey (range 4–79) with omeprazole treatment in 21 ZES patients (9). Furthermore, fundic argyrophil carcinoids developed in 3/7 ZES-MEN 1 patients treated with omeprazole

during the survey (9). Differences between the experience of Maton et al. (10) and our own observations (9) might be related to population characteristics. The patient group studied by Maton et al. (10) included 2 women and 15 men and 18% of ZES-MEN 1. In contrast, our patient group was more representative of ZES with 8 women and 13 men and 33% of ZES-MEN 1 (9).

Since gastrinoma tumoral growth could have enhanced serum gastrin during the study, our patients treated with omeprazole were divided into 2 groups according to their tumoral status (gastrinoma growth and no gastrinoma growth) (9). The serum gastrin level increased significantly only in the group with gastrinoma growth (Table). The fundic argyrophil cell density increased significantly in both groups but to a much lesser extent in the group without gastrinoma growth (Table) (9). These results strongly suggested that in patients treated with omeprazole treatment, the increase in fundic argyrophil cell density was mainly related to the increase in serum gastrin which was in most part due to gastrinoma growth. However, in some patients without detectable gastrinoma growth we noticed individual linear correlations between fundic argyrophil cell densities and the duration of treatment (Fig. 4), suggesting that prolonged hypochlorhydria itself could influence fundic argyrophil cell proliferation (9).

It is not known whether the increase in antral gastrin cell density under omeprazole may be responsible, at least in part, for the increase in serum gastrin levels. However, the antral gastrin cell densities, which were not correlated with serum gastrin at the beginning of the study ( $r = 0.05$ ), significantly did so after a median treatment duration of 36 months ( $r = 0.62$ ,  $p = 0.006$ ) (9). Furthermore,

**Table**

Evolution of serum gastrin, fundic argyrophil and antral gastrin cell density (median values) during omeprazole treatment in 21 ZES patients, according to the evolution of the gastrinoma tumoral process (modified from ref. 7)

	Point of the study		First vs last variations (%)	p-value
	First	Last		
Serum gastrin (Pg/ml)				
No gastrinoma growth (n = 13)	260	255	+48	NS
Gastrinoma growth (n = 8)	677*	5 242*	+179*	<0.02
Fundic argyrophil cell density (No. of cells/unit area)				
No gastrinoma growth (n = 13)	21.2	26.8	+34	<0.02
Gastrinoma growth (n = 8)	29.7	66.6*	+136	<0.02
Antral gastrin cell density (No. of cells/unit area)				
No gastrinoma growth (n = 13)	18.1	32.8	+43	0.003
Gastrinoma growth (n = 8)	19.6	44.1*	+131*	<0.02

\* p < 0.05 vs values of the same parameters in the group without gastrinoma growth (U test)

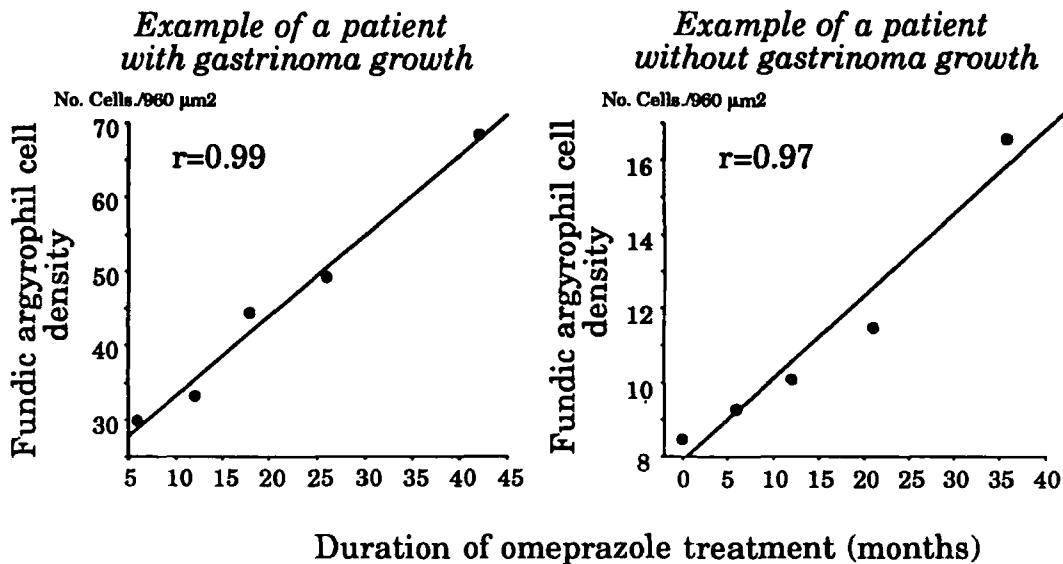


Fig. 4. Examples of linear correlations between fundic argyrophil cell densities and the corresponding durations of omeprazole treatment in 2 patients with the ZES, one in whom gastrinoma growth was evidenced and the other in whom no gastrinoma growth during treatment was seen (personal data).

the percentage of increase in antral gastrin cell density during the study was positively correlated with the percentage of increase in serum gastrin ( $r = 0.82$ ,  $p = 0.0002$ ) (9).

The number of patients with ZES under other treatments (ranitidine or octreotide) was too small to evaluate the effect on endocrine cell proliferation. Let us just indicate that in 4 patients treated with octreotide for 4 to 5 years, the median fundic argyrophil cell density did not increase while the serum gastrin level decreased in 3 patients and remained unchanged in the fourth patient (personal data).

#### Influence of MEN 1

Until now, fundic argyrophil carcinoids were only observed in patients in whom ZES was associated with MEN 1 (6-8). We searched for a difference in fundic argyrophil cell density between patients with sporadic ZES and patients with ZES-MEN 1 (7). When adjusted for sex, the mean argyrophil cell density was higher (+48.5%,  $p = 0.06$ ) in 17 patients with ZES-MEN 1 than in 31 patients with sporadic ZES (7). Such difference (not significant) was also found in the subgroup of patients treated

with omeprazole (+40%) and in the subgroup of patients treated with ranitidine or octreotide (+60%) (7). The qualitative evaluation of fundic argyrophil cell pattern according to Solcia's classification (17) showed marked differences between the 2 groups. In our material, normal pattern was noted in 16% of the patients with the sporadic type disease, diffuse cell hyperplasia in 71% and linear cell hyperplasia in 13%. No patient with ZES-MEN 1 had normal pattern, 53% and 47% of them had diffuse and linear hyperplasia respectively (7). Carcinoids were observed only in patients with associated MEN 1. Maton et al. (10) also noted, but in a smaller number of patients ( $n = 3$ ), that argyrophil cell densities were higher in patients with ZES-MEN 1 than in sporadic ZES.

#### Other factors

It is possible that the sex plays a role for fundic endocrine cell proliferation. In rats treated with omeprazole, the percentage of animals who developed fundic argyrophil carcinoid tumors was higher in females than in males (22). In patients with untreated duodenal ulcer, the number of fundic argyrophil cells was higher in females than in males (23). In patients with the ZES, we found such a difference in argyrophil cell density between women ( $51 \pm 8$  cells/unit area,  $n = 17$ ) and men ( $33 \pm 4$  cells/unit area,  $p < 0.05$ ,  $n = 31$ ) (7).

The age seems to have an influence on argyrophil cell population in man (24). We found in patients with the ZES that argyrophil cell densities were roughly stable in young and old women while they declined in old men (7).

In different studies, the duration of the disease which, however, is difficult to estimate, was not correlated with fundic argyrophil cell densities (5, 9–10).

#### Fundic argyrophil carcinoid tumors in ZES

In two recent papers, Solcia et al. reported 14(6) and then 19(8) cases of ZES patients with fundic argyrophil carcinoid tumors. The tumors were either solitary or multiple and were distributed throughout the oxyntic mucosa (6). In our series the size of the tumors varied from 0.5 mm (threshold defined by Solcia et al. (17)) to 3–4 cm (7). The reported tumors were intramucosal and infiltrated the muscularis mucosa or the submucosa (6–7). Until now, liver metastases from fundic argyrophil carcinoid tumors have not been reported, while metastatic lymph nodes have (6). It is known that fundic carcinoid tumors occurring in patients with atrophic gastritis can be malignant (3).

These tumors were argyrophil (Grimelius, Sevier-Munger) and immunoreacted with chromogranin A (6–7). They were mostly composed of typical or atypical ECL cells (6–7). Some of them also contained additional cell types (4). All degrees of argyrophil cell hyperplasia were

noted in the non-tumoral fundic mucosa (6–7). The fundic argyrophil cell density in patients without carcinoids was sometimes higher than that in patients with carcinoids (7).

The development of carcinoids does not seem to be influenced by the sex (6–7) and the treatment received, since some patients were treated with omeprazole (7), some with ranitidine (6–7) while others probably never received any antisecretory drug (6). In patients with carcinoids, the serum gastrin levels varied from twice the upper normal limit to more than 100 times that limit (7).

The only factor which differentiates the ZES patients with carcinoids from those without seems to be the association to MEN 1 syndrome (6–8). Solcia et al. mentioned 3 possible but unpublished cases occurring in sporadic ZES (8), but it is not proven that these patients really had sporadic ZES. In our series we found 5 patients with carcinoids among 17 ZES-MEN 1 patients studied (29.5%) (7). This high percentage may indicate that the number of new recognized cases will rapidly increase in the future.

MEN 1 is an inherited disorder in which endocrine tumors develop in pancreas, parathyroid glands, anterior pituitary gland and in adrenal glands (1). Among ZES patients, only 25% have also MEN 1 syndrome (1). In patients with MEN 1, the development of pancreatic (25) and parathyroid tumors (26) is the consequence of two mutational events on the MEN 1 gene. The first one is carried in the germ line, and the second one is acquired (loss of the normal allele of the gene). We do not know if the same genetic mechanisms are responsible for the development of fundic argyrophil carcinoid tumors in patients with ZES-MEN 1.

#### Conclusion

In patients with ZES, the proliferation of fundic argyrophil cells is mainly under gastrin control. In patients treated with omeprazole, the density of these cells is higher than in patients treated with other antisecretory drugs. However, during omeprazole therapy, the increase in argyrophil cell density and in serum gastrin concentration seems mostly due to gastrinoma tumoral growth. An effect of the duration of achlorhydria induced by omeprazole treatment cannot be eliminated. Indeed, antral gastrin cells only increased in omeprazole-treated patients and correlation between fundic argyrophil cell density and the duration of omeprazole treatment was found in at least half of the patients. Whether the increase in antral gastrin cells may also modify serum gastrin levels remains to be determined. Fundic carcinoid tumors in ZES only occur in patients with MEN 1. In this small subgroup of patients, the number of newly recognized tumors will probably increase. The mechanism for the tumorigenesis of fundic carcinoid tumors is not known but could be the same as for pancreatic and parathyroid tumors in MEN 1.

## REFERENCES

1. Mignon M, Bonfils S. Diagnosis and treatment of Zollinger-Ellison syndrome. *Baillieres Clin Gastroenterol* 1988; 2: 677-98.
2. Bordi C, Cocconi G, Togni R, Vezzadini P, Missale G. Gastric endocrine cell proliferation. Association with Zollinger-Ellison syndrome. *Arch Pathol* 1974; 98: 274-8.
3. Carney JA, Go VL, Fairbanks VF, Moore SB, Alport EC, Nora FE. The syndrome of gastric argyrophil carcinoid tumors and nonantral gastric atrophy. *Ann Intern Med* 1983; 99: 761-6.
4. Mignon M, Lehy T, Bonnefond A, Ruzniewski P, Labeille D, Bonfils S. Development of gastric argyrophil carcinoid tumors in a case of Zollinger-Ellison syndrome with primary hyperparathyroidism during long-term antiseecretory treatment. *Cancer* 1987; 59: 1959-62.
5. Lehy T, Mignon M, Cadiot G, et al. Gastric endocrine cell behavior in Zollinger-Ellison patients upon long-term potent antiseecretory treatment. *Gastroenterology* 1989; 96: 1029-40.
6. Solcia E, Capella C, Fiocca R, Rindi G, Rosai J. Gastric argyrophil carcinoidosis in patients with Zollinger-Ellison syndrome due to type I multiple endocrine neoplasia. A newly recognized association. *Am J Surg Pathol* 1990; 14: 503-13.
7. Lehy T, Cadiot G, Mignon M, Ruzniewski P, Bonfils S. Influence of multiple endocrine neoplasia type I on gastric endocrine cells in patients with the Zollinger-Ellison syndrome. *Gut* 1992; 33: 1275-9.
8. Solcia E, Fiocca R, Sessa F, et al. Morphology and natural history of gastric endocrine tumors. In: Håkanson R, Sundler F, eds. *The stomach as an endocrine organ*. Amsterdam: Elsevier, 1991: 473-98.
9. Cadiot G, Lehy T, Ruzniewski P, Bonfils S, Mignon M. Gastric endocrine cell evolution in patients with Zollinger-Ellison syndrome. Influence of gastrinoma growth and long-term omeprazole treatment. *Dig Dis Sci* (in press).
10. Maton PN, Lack EE, Collen MJ, et al. The effect of Zollinger-Ellison syndrome and omeprazole therapy on gastric oxyntic endocrine cells. *Gastroenterology* 1990; 99: 943-50.
11. Helander HF. Oxyntic mucosa histology in omeprazole-treated patients suffering from duodenal ulcer or Zollinger-Ellison syndrome. *Digestion* 1986; 35: (Suppl. 1): 123-9.
12. Bardram L, Thomsen P, Stadil F. Gastric endocrine cells in omeprazole-treated and untreated patients with the Zollinger-Ellison syndrome. *Digestion* 1986; 35: (Suppl. 1): 116-22.
13. Hage E, Hendel L, Bardram L, Gustafsen J, Hendel J, Stentoft P. Histopathology of the gastric oxyntic mucosa in two different patient groups during long-term treatment with omeprazole. *Gastroenterology* 1991; 100: A79.
14. D'Adda T, Bertelè A, Pilato FP, Bordi C. Quantitative electron microscopy of endocrine cells in oxyntic mucosa of normal human stomach. *Cell Tissue Res* 1989; 255: 41-8.
15. Simonsson M, Eriksson S, Håkanson R, et al. Endocrine cells in the human oxyntic mucosa. A histochemical study. *Scand J Gastroenterol* 1988; 23: 1089-99.
16. D'Adda T, Corleto V, Pilato FP, et al. Quantitative ultrastructure of endocrine cells of oxyntic mucosa in Zollinger-Ellison syndrome. Correspondence with light microscopic findings. *Gastroenterology* 1990; 99: 17-26.
17. Solcia E, Bordi C, Creutzfeldt W, et al. Histopathological classification of nonantral gastric endocrine growths in man. *Digestion* 1988; 41: 185-200.
18. Borch K, Renvall H, Liedberg G, Andersen BN. Relations between circulating gastrin and endocrine cell proliferation in the atrophic gastric fundic mucosa. *Scand J Gastroenterol* 1986; 21: 357-63.
19. Larsson H, Carlsson E, Mattsson H. Plasma gastrin and gastric enterochromaffin-like cell activation and proliferation. Studies with omeprazole and ranitidine in intact and antrectomized rats. *Gastroenterology* 1986; 90: 391-9.
20. Bardram L. Progastrin in serum from Zollinger-Ellison patients. An indicator of malignancy? *Gastroenterology* 1990; 98: 1420-6.
21. Ryberg B, Bishop AE, Bloom SR, et al. Omeprazole and ranitidine, antiseecretagogues with different modes of action, are equally effective in causing hyperplasia of enterochromaffin-like cells in rat stomach. *Regul Pept* 1989; 25: 235-46.
22. Ekman L, Hansson E, Havu N, Carlsson E, Lundberg C. Toxicological studies on omeprazole. *Scand J Gastroenterol* 1985; 20 (Suppl. 108): 53-69.
23. Helander HF, Simonsson M, Sundler F, Rutgersson K, Helander KG, Eriksson S. Histology of gastric biopsies from peptic ulcer patients before and after short-term treatment with omeprazole of H<sub>2</sub>-receptor antagonists. *Virchows Arch [A]* 1990; 417: 305-9.
24. Green DM, Bishop AE, Rindi G, et al. Enterochromaffin-like cell populations in human fundic mucosa: quantitative studies of their variations with age, sex, and plasma gastrin levels. *J Pathol* 1989; 157: 235-41.
25. Friedman E, Sakagushi K, Bale AE, et al. Clonality of parathyroid tumors in familial multiple endocrine neoplasia type 1. *N Engl J Med* 1989; 321: 213-6.
26. Thakker RV, Bouloux P, Wooding C, et al. Association of parathyroid tumors in multiple endocrine neoplasia type 1 with loss of alleles on chromosomes 11. *N Engl J Med* 1989; 321: 218-24.