

SALVAGE TREATMENT AFTER rINTERFERON α -2a IN ADVANCED NEUROENDOCRINE TUMORS

NICOLETTA ZILEMBO, ROBERTO BUZZONI, EMILIO BAJETTA, MARIA DI BARTOLOMEO, FILIPPO de BRAUD,
RITA CASTELLANI, LORENZO MAFFIOLI, LUIGI CELIO, EUGENIO VILLA, VITO LORUSSO, VINICIO FOSSER
and FRANCO BUZZI

The use of interferon (IFN) in neuroendocrine advanced tumors has achieved control of hormonal symptoms but low objective tumor response rate. In patients resistant to, or failing on, IFN a second line treatment may be required. Seventeen patients having received recombinant IFN α -2a as last treatment entered the study. There were 12 carcinoids, 3 medullary thyroid carcinomas, one Merkel cell carcinoma, and one neuroendocrine pancreatic tumor. Two different treatments were used: one radiometabolic therapy with metaiodobenzylguanidine (MIBG) in 3 patients with high MIBG uptake and one polychemotherapy regimen, including streptozotocin 500 mg/m² intravenously days 1, 2, 3 and epirubicin 75 mg/m² intravenously day 1, in the remaining 14 patients. Stable disease with relief of symptoms and tumor marker reduction was obtained in two patients receiving MIBG therapy, whereas the third patient had progressive disease. In the chemotherapy group only one partial response was obtained and neither tumor marker reduction nor subjective improvement were seen. Our second-line treatment was not especially effective but may be considered for rapidly progressive and/or symptomatic disease. The radiometabolic therapy appears promising in symptomatic patients with small tumor burden whereas our chemotherapy regimen appears ineffective.

The APUD tumors, characterized by amine precursor uptake and decarboxylation, represent a heterogeneous family of neuroendocrine carcinomas. The theory of their common embryological origin within the neural crest is sustained by similar cytochemical and ultrastructural properties (1). Unfortunately, therapeutic approaches in metastatic disease often do not consider the different biological behaviors of these neoplasms. Surgical excision

may, even when it is not radical, give good palliation of tumor-related symptoms. Many of these tumors are slowly growing and reduction of the tumor burden can have a positive impact on quality of life and survival. However, when surgery is not feasible, medical treatment has to be considered. The use of interferons at different doses and schedules has achieved control of hormonal symptoms but a low objective tumor response rate (2-4). Efficacy of chemotherapy has seldom been reported for single agents, such as 5-FU, doxorubicin and streptozotocin (STZ) (5-8). Better results have been obtained with polychemotherapy. The most promising combinations seem to be 5-FU and STZ (9) or 5-FU, doxorubicin, cyclophosphamide and STZ (10), but the association of STZ and doxorubicin has also been shown to induce objective response (11). External irradiation has doubtful value and it is generally considered ineffective although some authors disagree (12). Metaiodobenzylguanidine (MIBG) is a structural analog of the guanethidine located within the neurosecretory storage granules of adreno-sympathetic cells. The radio-

Received 12 November 1992

Accepted 21 November 1992

From the Italian Trials in Medical Oncology (I.T.M.O.) Group, Reference Center, Division of Medical Oncology B, Istituto Nazionale per lo Studio e la Cura dei Tumori, Milan, Italy (all authors).

Correspondence to: Dr Emilio Bajetta, Division of Medical Oncology B, Istituto Nazionale per lo Studio et la Cura dei Tumori, Via Venezian 1, I-20133 Milano, Italy.

Presented at the 3rd International Workshop on Neuroendocrine Tumors held in Lofoten, Norway, June 24-28, 1992.

iodinated molecule is taken up by these catecholamine producing and storing neuroendocrine tumors. The tumors with the highest uptake of MIBG and for which the best therapeutic results have been reported are pheochromocytomas and neuroblastomas (13). The relatively low effectiveness of the method in other neuroendocrine tumors has limited the experience of I-131-MIBG therapy (14–20); very few reports are available and so far only symptom relief and/or a reduction of biochemical markers have been obtained. On the basis of these background data, we decided to try the combination of STZ plus epirubicin, as well as radiometabolic therapy with MIBG, to see whether there was an appreciable uptake of MIBG in patients who previously had received recombinant interferon- α -2a (rIFN- α -2a).

Material and Methods

Patients. Patients with histologically documented advanced neuroendocrine tumors entered the study. All patients had received rIFN α -2a intramuscularly at 6×10^6 IU daily for an initial period of 8 weeks and then 3 times a week. The treatment had been given until disease progression (PD), or for at least 12 months in the presence of stable disease (SD) or partial response (PR). The other eligibility criteria were that the patients could have been previously treated with surgery and/or limited field radiotherapy and/or chemotherapy (excluding STZ and anthracyclines). The patients had to be aged ≤ 78 years and have a performance status (PS) of 0–2 (ECOG scale). Adequate renal (serum creatinine < 15 mg/l), hepatic (bilirubin < 30 mg/l) and hematological functions (WBC $\geq 4 \times 10^9$ /l and platelet count $\geq 120 \times 10^9$ /l) were required, as well as at least one measurable lesion suitable for disease evaluation. The exclusion criteria included CNS metastases, concomitant serious illness and a life expectancy of less than 3 months. Staging was performed before therapy and included physical examination, biochemical profile, chest x-rays, ECG, and abdominal ultrasound or computed tomography (CT).

Radioiodine MIBG scan. Patients eligible for MIBG therapy were selected by means of $^{131}\text{I}/^{123}\text{I}$ -MIBG scan. In 12/17 patients the scan was performed after an i.v. injection of 41.4 and 370 MBq of ^{131}I - and ^{123}I -MIBG respectively. Thyroid blockage was obtained by oral administration of iodine and potassium perchlorate. Whole body and planar images were produced at 24 h and, in some cases, also at 48 and 72 h.

Tumor marker analysis. The following tumor markers were determined: 5-hydroxyindolacetic acid (5-HIAA), neurons specific enolase (NSE) and calcitonin. The level of 5-HIAA was estimated by high performance liquid chromatography as the average of two 24-h urine collections. Calcitonin and NSE serum levels were determined by radioimmunoassay. Samples were drawn immediately before the start of treatment, and monthly thereafter.

Treatments. Two types of treatments were considered in this study. Radiometabolic therapy with ^{131}I -MIBG was used in cases where a high uptake on the lesions were found in the scan. A therapeutic dose of ^{131}I -MIBG was then administered as a 90-min infusion with an infusion pump. Thyroid blocking by iodine solution and triiodothyronine was started 7 days before therapy and maintained for 3 weeks. The injected activity was 5.5 GBq for one course, with a specific activity of more than 1.11 GBq/mg. Whole body scans with anterior and posterior views were routinely produced 5 days after the therapeutic administration of MIBG. A course of therapy was repeated every 8 weeks.

Patients who were considered unsuitable for radiometabolic treatment received combination chemotherapy with i.v. STZ (Zanosar, Upjohn Co, Milan, Italy) 500 mg/m² on days 1, 2 and 3, plus epirubicin 75 mg/m² i.v. on day 1. After adequate renal and hematological evaluation, the cycles were repeated every 3 weeks. A maximum of 7 cycles was administered to responsive patients. In the case of neutrophils $< 2 \times 10^9$ /l and/or platelets $< 100 \times 10^9$ /l, 75% of the dose was delivered; if neutrophil and/or platelet counts were $< 1.5 \times 10^9$ /l and/or platelets $< 75 \times 10^9$ /l, treatment was withheld until recovery.

Response and toxicity. Patients who had received at least 2 chemotherapy cycles or ^{131}I -MIBG treatments were considered evaluable for response. History was recorded and blood counts and blood biochemistry examinations performed before each treatment. Tumor measurement by ultrasound or CT and x-rays was repeated every 2 months. Flushing and diarrhea were checked frequently. Tumor response was defined according to the UICC criteria: complete remission (CR) was defined as the complete disappearance of all known disease for a minimum of 1 month; PR as $\geq 50\%$ decrease in the sum of the products of the two largest perpendicular diameters of all tumor masses for at least 1 month; SD as $< 50\%$ decrease or $< 25\%$ increase in the size of measurable lesions; PD as $\geq 25\%$ increase in any tumor lesion or the appearance of new lesions. All patients were considered evaluable for toxicity, which was classified according to the WHO criteria (21).

Results

Seventeen patients with advanced neuroendocrine tumors entered the study, which lasted from May 1990 until July 1991. The study was conducted by the Italian Trials in Medical Oncology (I.T.M.O.) Group, with the Division of Medical Oncology B at Milan's Istituto Nazionale Tumori as the Reference Center. The main characteristics of the patients are shown in Table 1; carcinoid was the predominant histologic type (midgut 3, foregut 7, breast 1, unknown 1). Table 1 also shows the sites of disease, all but one patient having multiple sites. As regards previous

Table 1
Main patient and tumor characteristics

No. of patients	17
Male/female	6/11
Median age, years (range)	58 (43–77)
Performance status (ECOG): 0–1	13/4
Histology	
Carcinoid	12
Merkel cell carcinoma	1
Medullary thyroid carcinoma	3
Neuroendocrine pancreatic tumor	1
Carcinoid syndrome	4
Abnormal 5-HIAA excretion	4
Disease sites	
Skin	4
Lymph nodes	10
Liver	11
Lung	3
Pancreas	2
Stomach	1
Bone	3
Other	2

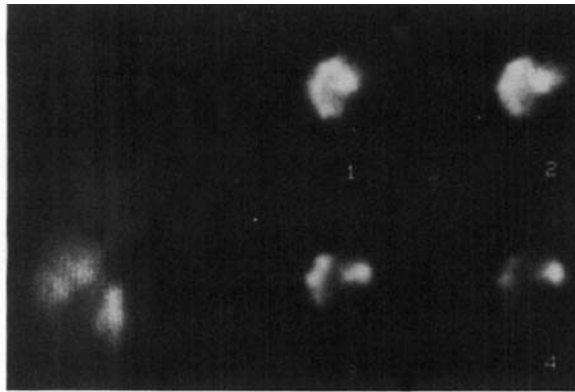
treatments, 8 cases had undergone radical surgery, 2 patients limited field radiotherapy, and two patients a chemotherapy regimen including 5-FU and cisplatin. All patients had received rIFN α -2a as their last treatment and, on entering the study, 13 cases were progressive after a median treatment time of 2 months (range 2–12), while 3 had SD and 1 PR after twelve months.

Seven of the twelve patients examined by radioiodine-MIBG scan showed a positive result, but only 3 of them were considered eligible for radiometabolic treatment (the other 4 patients were excluded due to an allergic reaction to iodine in 1 case and doubtful or insufficient uptake in the lesion in 3 cases). The remaining 14 patients received the polychemotherapy.

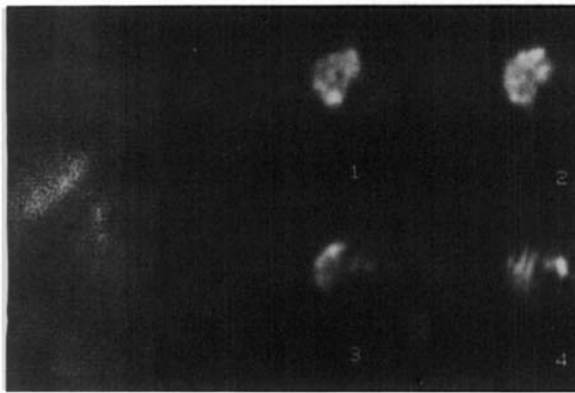
The results of ^{131}I -MIBG therapy are summarized in Table 2. The treatment was given to three females (55, 70 and 77 years old), two of whom received 9 courses with a cumulative activity of 42.15 GBq over 19 months. The first patient showed a slight reduction of liver and lymph node metastases, documented by SPECT imaging, but not by CT scan or ultrasound (Fig. 1). A slight reduction of 5-HIAA urinary excretion, resolution of diarrhea and improvement of performance status were also observed. Subjective relief of symptoms was obtained after the first course of therapy, while the initial regression of liver and lymph node disease was observed after 12 months of therapy and a cumulative dose of 25.9 GBq. In this patient, the therapy is still continuing with a follow-up of 20 months. In the second patient, subjective improvement, a small reduction of a supraorbital mass and stabilization of bone and liver metastases were observed for 19 months. The therapy has now been discontinued due to a worsening of diarrhea and general condition. The third woman received only two courses (11.1 GBq) due to rapidly progressive lung and skin metastases within three months. The treatment was well tolerated and no hematological toxic-

Table 2
Results of MIBG therapy

Patient	No. 1	No. 2	No. 3
Sex/Age (years)	Female/50	Female/70	Female/77
Diagnosis	Carcinoid tumor (ileum)	Carcinoid tumor (unknown origin)	Carcinoid tumor (lung)
Site of disease	Liver, lumbo-aortic and mediastinic lymph nodes	Ileum (resected), supra-orbital mass, liver, bone	Lung, liver, skin, lymph nodes
Carcinoid syndrome	Diarrhea, flushing, > 5HIAA urinary excretion	Diarrhea, hypotension	> 5-HIAA urinary excretion
Previous treatments	Surgery (ileum), r-Interferon	Radiotherapy (skull) r-Interferon	r-Interferon
Interval from diagnosis to 1st MIBG course (months)	17	15	4
Treatment duration (months)	> 19	19	3
No. of courses	9	9	2
Cumulative activity (GBq)	42.15	42.15	11.1
Response	SD	SD	PD
Survival (months)	20—alive	20—alive	5—exitus
Side effects	None	Moderate hypotension	None



a)



b)

Fig. 1. a) Planar (left) and tomographic (SPET, right) gamma camera images of patient No. 1 obtained 4 days after the first therapeutic administration of ^{131}I -MIBG. Pathological uptakes (hot areas) are present in mediastinum, liver and abdomen. b) Corresponding images obtained after 9 courses of ^{131}I -MIBG treatment. There is still uptake in the same areas but the uptake seems reduced.

ity was observed. Only in the second case did moderate, transient hypotension occur during the second course of therapy.

All the 14 cases treated with polychemotherapy were considered evaluable for response and toxicity. The median number of cycles was 4 (range: 2–7). One patient with Merkel cell carcinoma had PR after 2 months. The response duration calculated from the onset of response to progression was 5 months. Stabilization was observed in the 4 patients with SD or PR after IFN, and was maintained for 18, 17, 16 and 13 months respectively. Two of these patients refused further treatment after two and four cycles respectively. Nine patients showed PD, with a median time to progression of 3 months (range: 2–6). Two patients had abnormal 5-HIAA values but only one suffered from flushing and no effect on symptoms or on urinary markers was observed during the treatment. Absence of any reduction of tumor markers was also observed in the 3 patients with medullary thyroid carcinoma.

Four patients had high NSE levels and only one of them (with SD) showed a significant reduction in the marker. The treatment was administered in an outpatient setting, and no grade 4 toxicity was observed. Nausea or vomiting was mild to moderate in most patients, stomatitis was seen in 5 (grade 3 in one of them), and alopecia in all. None of the patients experienced renal toxicity although one had a liver dysfunction unrelated to the drugs and refused treatment after 4 cycles. Two patients had had dose reduction to 75% of the planned dose; in one patient, this was due to concomitant radiotherapy during the first 3 cycles; in the other one, the reason was non-drug-related increase in transaminase at the fourth cycle. After a median follow-up of 18 months from entering the study the 24-month probability of survival was 70%.

Discussion

The experience of ^{131}I -MIBG therapy in carcinoid tumors is still limited. Good palliation, but without significant objective responses, has been observed in carcinoid tumours by several authors (17–20). So far, only two complete responses have been reported (22). The major factors limiting the effectiveness of radiometabolic therapy in these tumors are inappropriate selection of patients and a large tumor mass. Only patients with high MIBG uptake that correlates with the extent of the disease should be selected for the therapy. For this reason only 3 of our 7 patients with a positive MIBG scan were treated. Only a moderate decrease of some tumor lesions was documented. It is known that large tumor masses reduce the effectiveness of radiometabolic treatment due to unfavorable dosimetric parameters and the only two patients reported in the literature as achieving complete remission had very small metastatic tumors.

The role of chemotherapy in the management of neuroendocrine malignancies is debatable due partly to different responsiveness of different types of tumor. The result of chemotherapy is sometimes only a reduction of tumor markers without any objective tumor regression. Some rather favorable results have, however, appeared in the literature: some authors have thus found anti-tumor activity of STZ in metastatic carcinoid tumors (6, 23, 24) while Schein et al. (8) found response only in islet cell carcinomas. Doxorubicin has demonstrated activity in carcinoid patients without heart disease, and also in patients failing to respond to STZ, while cisplatin alone appears to be inactive in such patients (25). Polychemotherapy seems to be more effective. With a combination of 5-FU and STZ response rates of 29% in islet cell carcinomas and of 20% in carcinoids have been reported (26). Even in combination treatments, cisplatin has failed to demonstrate good results in well-differentiated carcinoid tumors or islet cell carcinomas, although a higher response rate has been reported in anaplastic neuroendocrine carcinoma (27, 28).

Recently, superiority of STZ plus doxorubicin over that of STZ plus 5-FU in advanced islet cell carcinoma has been reported in terms of response rate and length of time to tumor progression (29). Only one of our patients obtained objective response with STZ plus epirubicin. This PR patient had Merkel cell carcinoma, and our finding thus confirms published reports that this is a chemotherapy responsive cancer (30, 31). Our poor overall response rate (7%) can be explained by the high percentage of carcinoid tumors, which seem to be only moderately responsive to STZ (8). Furthermore, our patients had all been previously treated with immunotherapy, and 3 of them had also received polychemotherapy and/or radiotherapy, thus reducing the probability of response to a second or a third-line treatment. Our data confirm that there is a considerable difference in the responsiveness of the various tumor types. A further therapeutic approach after IFN should only be considered in the presence of rapidly progressive disease, or symptoms which significantly interfere with daily activity, and no treatment should be given to SD or PR patients. It is possible that ¹³¹I-MIBG therapy might be used with benefit after palliative surgery in patients with small neuroendocrine tumors. In patients with a large tumor burden, the treatment can obviously relieve symptoms; in such cases higher doses could be given during each course, and the interval between courses prolonged. At present, polychemotherapy cannot be recommended for these patients, and so further phase II studies are needed.

ACKNOWLEDGEMENTS

The authors thank the Upjohn Co. (Milan, Italy) for providing Zanosar and Italian Trials in Medical Oncology (I.T.M.O.) Scientific Service for data management.

REFERENCES

- Pearse AG. The cytochemistry and ultrastructure of polypeptide hormone producing cells of the APUD series and the embryologic, physiologic and pathologic implications of the concept. *J Histochem Cytochem* 1969; 17: 303-13.
- Öberg K, Funa K, Alm G. Effects of leukocyte interferon on clinical symptoms and hormone levels in patients with midgut carcinoid tumors and carcinoid syndrome. *N Eng J Med* 1983; 309: 129-33.
- Moertel CG, Rubin J, Kvols LK. Therapy of metastatic carcinoid tumor and the malignant carcinoid syndrome with recombinant leukocyte α interferon. *J Clin Oncol* 1989; 7: 865-8.
- Smith DB, Scarffe JH, Wagstaff J, Johnston RJ. Phase II trial of rDNA α 2b interferon in patients with malignant carcinoid tumor. *Cancer Treat Rep* 1987; 71: 1265-6.
- Moertel CG. Clinical management of advanced gastrointestinal cancer. *Cancer* 1975; 36: 675-82.
- Moertel CG. Treatment of the carcinoid tumor and the malignant carcinoid syndrome. *J Clin Oncol* 1983; 1: 727-40.
- Engstrom PF, Levin FT, Moertel CG, Folsch E, Douglas HO. Streptozotocin plus fluorouracil versus doxorubicin therapy for metastatic carcinoid tumor. *J Clin Oncol* 1984; 2: 1255-9.
- Schein PS, O'Connell MJ, Blom J, et al. Clinical antitumor activity and toxicity of streptozotocin (NSC-85998). *Cancer* 1974; 34: 993-1000.
- Moertel CG, Hanley JA. Combination chemotherapy trials in metastatic carcinoid tumor and the malignant carcinoid syndrome. *Clin Cancer Trials* 1979; 2: 327-34.
- Bukowski RM, Johnson KG, Peterson RF. A phase II trial of combination chemotherapy in patients with metastatic carcinoid tumors. *Cancer* 1987; 60: 2891-5.
- Frame J, Kelsen D, Kemeny N, et al. A phase II trial of streptozotocin and adriamycin in advanced APUD tumors. *Am J Clin Oncol* 1988; 11: 490-5.
- Abrams RA, King D, Wilson F. Objective response of malignant carcinoid to radiation therapy. *Int J Radiat Oncol Biol Phys* 1987; 13: 869-73.
- Shapiro B. Summary, conclusions, and future directions of (131 I)-Metaiodo-benzylguanidine therapy in the treatment of neural crest tumors. *J Nucl Biol Med* 1991; 35: 357-63.
- Hoefnagel CA, den Hartog Jager FCA, Taal GB, Abeling NGGM, Engelsman EE. The role of 131 I-MIBG in the diagnosis and therapy of carcinoids. *Eur J Nucl Med* 1987; 13: 187-91.
- Von Moll L, McEwan AJ, Shapiro B, et al. Iodine-131 MIBG scintigraphy of neuroendocrine tumors other than pheochromocytoma and neuroblastoma. *J Nucl Biol Med* 1987; 28: 979-88.
- Adolph J, Kimmig B, Eisenhut M, Georgi P. Therapy of carcinoid tumors with 131 I-meta-iodo-benzyl-guanidine. Recent results. *Cancer Res* 1988; 110: 280-4.
- Bestagno M, Pizzocaro C, Pagliani R, Rossini PL, Guerra P. Results of (131 I) metaiodobenzylguanidine treatment in metastatic carcinoid. *J Nucl Biol Med* 1991; 35: 343-5.
- Hoefnagel CA, Taal BG, Valdes Olmos RA. Role of (131 I) metaiodobenzylguanidine therapy in carcinoids. *J Nucl Biol Med* 1991; 35: 346-8.
- Castellani MR, Di Bartolomeo M, Maffioli L, Zilembo N, Gasparini M, Buraggi GI. (131 I) metaiodobenzylguanidine therapy in carcinoid tumors. *J Nucl Biol Med* 1991; 35: 349-51.
- Colombo L, Vignati A, Lomuscio G, Dottorini ME. Preliminary results of (131 I) metaiodobenzylguanidine treatment in metastatic carcinoid tumors. *J Nucl Biol Med* 1991; 35: 352-4.
- WHO/UICC Handbook for reporting results of cancer treatment. WHO Offset publication no. 48. Geneva, 1978.
- McEwan AJB. Treatment of patients with metastatic carcinoid tumor with (131 I)-Metaiodobenzylguanidine: Abstract book of the 'International Workshop on the role of (131 I) Metaiodobenzylguanidine in the treatment of neural crest tumors'. Rome (Italy, September 6-7) Sorin Biomedical, 1991 p. 56.
- Stolinsky DC, Sadoff L, Braunwald J, Bateman JR. Streptozotocin in the treatment of cancer. Phase II study. *Cancer* 1972; 30: 61-7.
- Feldman JM, Quicquel RE, Murocek RL, et al. Streptozotocin treatment of metastatic carcinoid tumors. *South Med J* 1972; 65: 1325-7.
- Moertel CG, Rubin J, O'Connell M. Phase II study of cisplatin therapy in patients with metastatic carcinoid tumors and malignant carcinoid syndrome. *Cancer Treat Rep* 1986; 70: 1458-60.
- Chernicoff D, Bukowski RM, Groppe CW, Hewlett JS.

- Combination chemotherapy for islet cell carcinoma and metastatic carcinoid tumors with 5-fluorouracil and streptozotocin. *Cancer Treat* 1979; 63: 795-6.
27. Rougier P, Oliveira J, Ducrex M, Theodore C, Kac J, Droz JP. Metastatic carcinoid and islet cell tumors of the pancreas: a phase II trial of the efficacy of combination chemotherapy with 5-fluorouracil, doxorubicin and cisplatin. *Eur J Cancer* 1991; 27: 1380-2.
 28. Moertel CG, Kvols LK, O'Connell M, Rubin J. Treatment of neuroendocrine carcinomas with combined etoposide and cisplatin. *Cancer* 1991; 68: 227-32.
 29. Moertel CG, Lefkopoulo M, Lipsitz S, Hahn RG, Klaasen D. Streptozotocin-doxorubicin, streptozotocin-fluorouracil, or chlorozotocin in the treatment of advanced islet cell carcinoma. *N Engl J Med* 1992; 326: 519-23.
 30. Feun LG, Savaraj N, Legha SS, Silva EG, Benjamin RS, Burgess MA. Chemotherapy for metastatic Merkel cell carcinoma. *Cancer* 1988; 62: 683-5.
 31. Wynne CJ, Kearsley JH. Merkel cell tumor. A chemosensitive skin cancer. *Cancer* 1988; 62: 28-31.