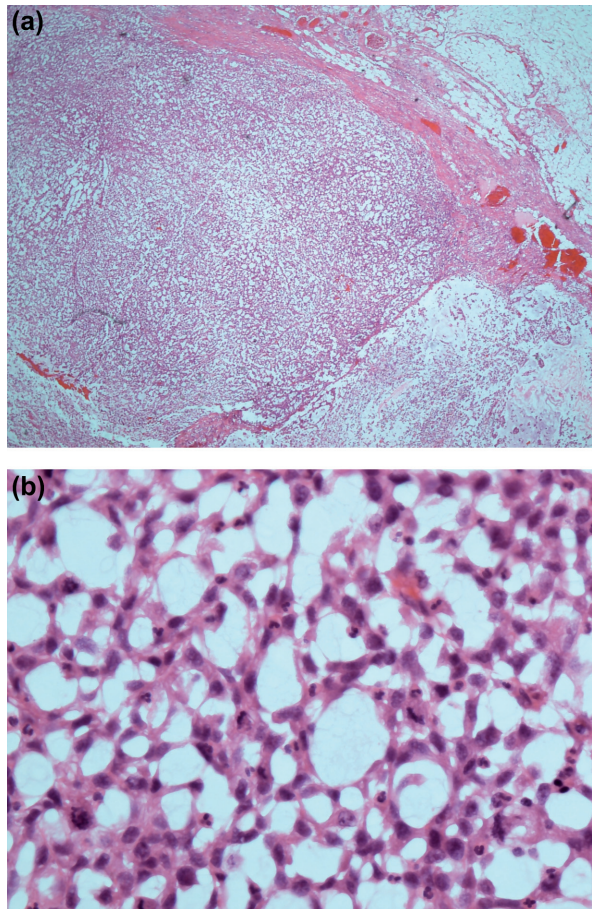
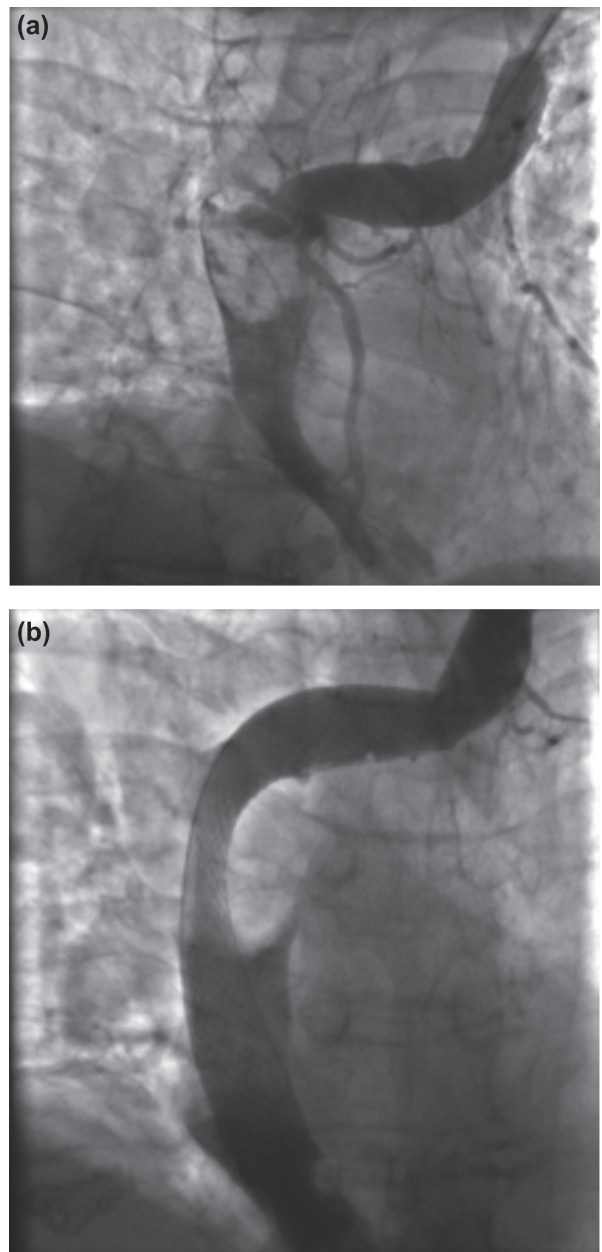


Supplementary material for Song J. et al. Myxofibrosarcoma directly invading superior vena cava causing obstruction successfully relieved by endovascular stent. Acta Oncol 2015;54:141–3.



Supplementary Figure 1a. Microscopic appearance (scanning/low power magnification, $\times 20$, H + E) of omental tumour deposit: circumscribed spindle cell mass with abundant myxoid stroma. Figure 1b. Microscopic appearance (high power magnification, $\times 400$, H + E) of omental tumour deposit: malignant spindle cells with pleomorphic nuclei and brisk mitotic activity.

Supplementary Video 1. Pre-operation
Supplementary Video 2. Post-operation



Supplementary Figure 2. Fluoroscopic images of SVC obstruction before (a) and after (b) endovascular stent.